

Mastoid Abscess in Acute and Chronic Otitis Media

MAZITA Ami¹, Zahirrudin ZAKARIA², GOH Bee See¹, Asma ABDULLAH¹, Lokman SAIM¹

Submitted: 1 Nov 2009

Accepted: 18 Mar 2010

¹ Department of Otorhinolaryngology–Head and Neck Surgery, Faculty of Medicine, Universiti Kebangsaan Malaysia Medical Centre, 56000 Cheras, Kuala Lumpur, Malaysia

² Department of Otorhinolaryngology, Hospital Pulau Pinang, 10990 Pulau Pinang, Malaysia

Abstract

Background: Mastoid abscess remains a recognised complication of otitis media despite the advent of antibiotics. The objectives of this study were to describe the risk factors in patients with mastoid abscess following acute and chronic otitis media and discuss the management of this infection.

Method: A retrospective analysis was done on all patients who underwent mastoidectomy for mastoid abscess from January 2002 to December 2007. Data on the patients' presentation, associated complications, management, and follow-up were analysed.

Results: A total of 12 patients were enrolled in this study population. Group A consisted of patients with mastoid abscess preceded by acute otitis media, while Group B consisted of patients with mastoid abscess and chronic otitis media. In Group A ($n = 7$), 4 patients had a pre-morbid immunocompromised condition, but they did not have cholesteatoma. None of the patients in Group B ($n = 5$) had any pre-morbid illnesses. Out of 12 patients, 7 patients had associated extracranial complications, and 1 patient had intracranial complications. Most patients recovered well after mastoidectomy. Recurrence was noted in 1 patient who had acute lymphoblastic leukaemia.

Conclusion: Mastoid abscess is still a recognised complication of acute otitis media, especially in patients who are immunocompromised. Immunocompetent patients may also develop mastoid abscess following chronic otitis media associated with cholesteatoma. Thus, early treatment of otitis media and close vigilant follow-up are advocated to ensure prompt detection of mastoid abscess complications.

Keywords: abscess, cholesteatoma, complications, immunocompromised patient, mastoiditis, otitis media, otology; head neck

Introduction

In the era of antibiotics, mastoid abscess is an uncommon complication of otitis media. This has resulted in a decline in the incidence of mastoidectomy performed for mastoid abscess. Nevertheless, there are still a number of patients who develop mastoid abscess, which requires prompt diagnosis and management. Records of patients who underwent mastoidectomy for mastoid abscess at Universiti Kebangsaan Malaysia Medical Centre (UKMMC) were reviewed. The objective of this review was to study the characteristics of patients who may have a higher risk of developing mastoid abscess following acute or chronic otitis media (COM).

Materials and Methods

This is a retrospective analysis of patients who underwent mastoidectomy for mastoid abscess in UKMMC from 2002 to 2007. The operative census was reviewed to identify patients who underwent mastoidectomy for mastoid abscess. The medical records of these patients were reviewed to confirm the diagnosis of mastoid abscess intra-operatively. The diagnosis of mastoid abscess was defined by findings of pus within the coalescent mastoid air cells. This study was approved by the Research and Ethics Committee of UKMMC (FF-242-2008).

Results

A total of 13 patients were identified in this study, and their ages ranged 3–70 years old with a mean of 30.4 years old. Further data of 1 patient could not be traced and had to be omitted, which left a total of 12 cases. The patients were classified into 2 groups: Group A consisted of patients with mastoid abscess preceded by acute otitis media (AOM), and Group B consisted of patients with mastoid abscess and underlying COM. AOM was defined as having symptoms for duration of less than 12 weeks, and cases were classified as COM when symptoms persisted for 12 weeks or longer. All patients in this series presented with unilateral ear infection.

Group A: Patients diagnosed with AOM with mastoid abscess

There were 7 patients categorised into Group A (Table 1). All paediatric patients ($n = 3$, age less than 12 years old) in this study were in this group. These patients had aural symptoms between 3 and 28 days prior to presentation. Post-auricular swelling was present in 3 patients, mastoid pain was present in 4 patients, and otorrhoea was present in 2 patients. Otoloscopic examination revealed perforated tympanic membrane in 2 patients.

There were 5 out of 7 patients who had other associated complications. There were also 4 out of 7 patients in this group who had pre-morbid conditions leading to a relatively immunocompromised state compared to the other subjects. Cholesteatoma, however, was not noted in any of these patients.

Group B: Patients diagnosed with mastoid abscess and underlying COM

There were 5 patients categorised into Group B (Table 2). In this group, the patients had chronic aural symptoms for 3 to 12 months and acute (new) symptoms for 2 to 6 weeks prior to presentation. Post-auricular swelling was present in 3 patients, mastoid pain was present in 4 patients, and otorrhoea was present in 3 patients. Otoloscopic examination revealed that all patients had a perforated tympanic membrane. It was noted that only 3 out of the 5 patients had other associated complications. All 3 patients had underlying cholesteatoma, but none of these patients had any pre-morbid illnesses.

Associated complications of otitis media

Out of 12 patients, 8 (66.7%) had complications of mastoiditis. These were mainly

extracranial complications, in 7 out of 8 patients: facial nerve palsy, in 3 patients, Bezold's abscess, in 3 patients (Figure 1), and zygomatic root abscess in 1 patient (Figure 2). In this series, only 1 patient had an associated intracranial complication of meningitis.

Management and follow-up

All patients were admitted and started on broad-spectrum intravenous antibiotics. Intravenous ceftriaxone was chosen because of its good blood-brain barrier penetration. Ceftriaxone was administered at a dose of 1 g daily, unless patients had intracranial complications, which required a dose of 2 g twice daily. The type of antibiotics was modified according to the culture results. The duration of antibiotic treatment was 2 weeks in all patients.

The bacteria isolated from patients' pus culture were *Staphylococcus aureus* in 3 patients, *Klebsiella pneumoniae* in 2 patients, coagulase-negative *Staphylococcus* spp in 1 patient and *Pseudomonas aeruginosa* in 1 patient. There were 2 patients with mixed growth, but the cultures contained predominantly *Enterococcus* spp. The other 5 patients had no growth on operative specimen or swab culture.

All of the patients in this series had mastoid exploration for abscess drainage and eradication of diseased mastoid air cells. Modified radical mastoidectomy was performed in almost half of the patients (5 out of 12 patients). Cortical mastoidectomy with myringotomy and ventilation tube insertion was performed in 4 patients, and 3 of those patients had AOM. Radical mastoidectomy was only performed in 2 patients (1 from each group).

Post-operatively, all patients had a good recovery. The average follow-up period was 24 months (range 8–58 months), and 2 out of 12 patients were lost during the post-operative follow-up. Only 1 patient with acute lymphoblastic leukaemia (ALL) in Group A had a recurrence of mastoid abscess, which occurred 1 month later.

The patient with ALL developed AOM while undergoing chemotherapy; the patient was treated with amoxicillin. Despite treatment compliance, the patient developed lower motor neuron facial nerve palsy 5 days later. Radical mastoidectomy was performed, which showed a bony dehiscence over the horizontal segment of the facial nerve which was covered by granulation tissue. The stapes suprastructure was also absent. Post-operatively, the facial nerve palsy improved from House–Brackmann grade IV to grade II. However, he had another episode of AOM with facial nerve

Table 1: Demographics of patients diagnosed with acute otitis media with mastoid abscess (Group A)

Patient	Age (years)	Pre-morbid condition	Duration of symptoms (days)	Other complications	Type of mastoid surgery	Duration of follow-up (months)
NA	3	Nil	3	None	Cortical	lost to follow-up
LMK	48	DM, HT	7	Meningitis	MRM	58
MS	6	ALL	5	Facial nerve palsy	Radical	lost to follow-up
WQE	7	BTM	14	Zygomatic root abscess	Cortical	14
CKC	46	Nil	30	Facial nerve palsy	Cortical	10
CCW	70	DM	21	Bezold's abscess	MRM	8

Abbreviation: ALL = acute lymphoblastic leukaemia, BTM = beta thalassaemia major, DM = diabetes mellitus, HT = hypertension, MRM = modified radical mastoidectomy

Table 2: Demographics of patients diagnosed with acute otitis media with mastoid abscess (Group B)

Patient	Age (years)	Duration of acute symptoms (days)	Cholesteatoma	Other complications	Type of mastoid surgery	Duration of follow-up (months)
NH	37	4	Yes	None	MRM	50
SN	29	4	Yes	None	MRM	24
AU	22	6	Yes	Facial nerve	Radical	10
AH	43	2	No	Bezold's abscess	MRM	18
WJ	14	4	No	Bezold's abscess	Cortical	8

None of the patients had pre-morbid condition. Abbreviation: MRM = modified radical mastoidectomy

palsy grade V a month later. Unfortunately, due to pancytopenia and a poor general condition, he was deemed unfit for another mastoid exploration. This patient later succumbed to the underlying haematological malignancy.

Discussion

The complications of otitis media are broadly categorised into extracranial and intracranial complications. Extracranial complications (such as mastoiditis, subperiosteal abscess, facial paralysis, and labyrinthitis) and intracranial complications (such as cerebral or extradural abscess, meningitis, focal encephalitis, lateral sinus thrombosis, and otic hydrocephalus) are more likely to be associated with AOM than COM (1-3).

Since the introduction of antibiotics in the 1940s, the incidence of acute mastoiditis and surgical intervention has declined. Recent

publications, however, have noted an increase in the incidence of acute mastoiditis following AOM in children (4,5). Conversely, there has been a reduced incidence of COM since the 1990s. However, the rate of extracranial and intracranial complications has remained stable (6). There have been significant socioeconomic improvements in many countries during this time. This is important because the established risk factors associated with COM include low socioeconomic class, malnutrition, and congested living conditions (7). Therefore, these studies seem to suggest an increased incidence of mastoiditis following AOM compared with COM.

Mastoiditis has often been recognised as an extracranial complication of otitis media when patients develop tender post-auricular swelling. The current treatment of mastoiditis is mainly antibiotics with surgery reserved to myringotomy (5,8). Mastoid abscess may develop as a complication of mastoiditis following both AOM and COM (9-11). It occurs when purulent material

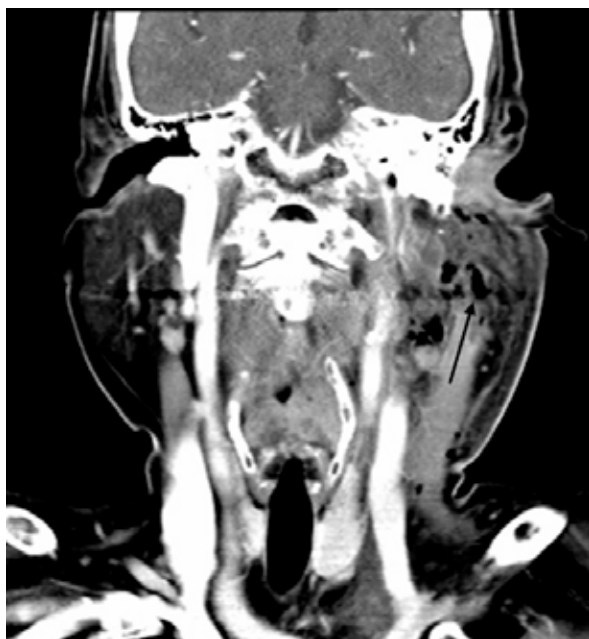

Figure 1: Coronal CT scan of a patient diagnosed with left mastoid abscess and Bezold's abscess (arrow)

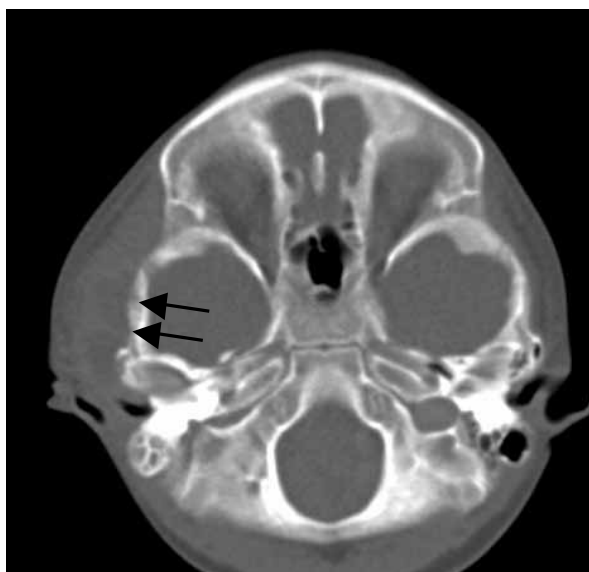


Figure 2: Axial CT scan of temporal bone showing right mastoid abscess and zygomatic root abscess (arrows)

collection accumulates within the middle ear and mastoid air cells, and it is often accompanied by granulation tissue. Surgical intervention is still the most common treatment for mastoid abscess. Therefore, it is important to distinguish mastoid abscess from uncomplicated mastoiditis and manage patients accordingly.

The most common clinical presentation of mastoid abscess in this series was a tender, fluctuant post-auricular swelling, which was similar to other cases in the literature (11,12). Otorrhoea was less common, and facial asymmetry, neck swelling, and meningism were even rarer. All of the patients with cholesteatoma had a history of chronic otorrhoea since childhood.

Complications following COM were more prevalent in subjects with cholesteatoma (13). Mustafa et al. showed that 15% of patients with COM had associated cholesteatoma, and one-third of them presented with complications. In COM without cholesteatoma, only 6.7% presented with complications. In the current series, the numbers were too small to make any significant comparison; however, 3 out of 5 patients with mastoid abscess following COM had cholesteatoma. Interestingly, the incidence of multiple complications can occur between 11% and 58% of cases and appears to be more prevalent in patients with intracranial complications (13–15).

Not surprisingly, the complication rate following COM has been reported to be higher than that following AOM (14,15), but caution should be exercised in young children with AOM because intracranial complications may occur relatively rapidly in the course of the disease (16). In this series, there was only 1 patient with meningitis as a complication of mastoid abscess. However, patients with mastoiditis or mastoid abscess who did not undergo mastoid surgery was excluded; therefore, the series may not have captured these cases.

In our centre, patients with suspected mastoid abscess following mastoiditis were promptly admitted and commenced on broad-spectrum intravenous antibiotics. A high-resolution CT of the temporal bone and contrast-enhanced CT of the brain were also performed in all patients. Mastoidectomy with abscess drainage was indicated when there was purulent collection clinically, evidence on the CT scan or in patients with cholesteatoma.

The predominant organisms cultured in this series were *Staphylococcus aureus* and *Klebsiella pneumoniae*; however, there was no single predominant organism in AOM or COM. There were 5 (42%) patients' samples that exhibited no

growth on routine cultures. Previous antibiotic treatment may have resulted in the absence of bacterial growth (4). In addition, tests for anaerobic cultures were not routinely performed in our institution when anaerobes are expected to be prevalent in COM. Previous studies have shown that common organisms in AOM include *Streptococcus pneumoniae* and *Haemophilus* spp. whereas common organisms in COM include *Proteus mirabilis*, *Enterococcus* spp., and *Pseudomonas aeruginosa* (5,13–15,17).

Mastoidectomy was performed expediently once the patient's medical condition was stabilised, and the decision to bring down the posterior canal wall or to perform radical mastoidectomy was depended on the intra-operative findings. Generally, intra-operative findings of intact ossicles with no cholesteatoma indicated cortical mastoidectomy with myringotomy (if the tympanic membrane was intact). In this series, intra-operative findings of ossicular erosion, including erosion of the stapes suprastructure, led to radical mastoidectomy in two patients.

Interestingly, serious co-morbidities were noted to be present in patients who developed mastoid abscess following AOM. The only 4 (25%) patients with pre-morbid illness were those who developed mastoid abscess following AOM. These pre-morbid conditions included ALL in 1 patient, BTM in 1 patient, and diabetes mellitus in 2 patients. It is postulated that an immunocompromised state due to illness may make a patient susceptible to developing mastoid abscess following AOM.

Factors that have been shown to influence the spread of infection include the type and virulence of the infecting organism, host resistance, and the adequacy of treatment (15). Patients with haematological malignancy, such as ALL, may present with leukaemic infiltration of the temporal bone; however, this is uncommon. Moreover, surgical findings often revealed greenish soft tissue mass with gelatinous fluid within the middle ear (18), which was not evident in our patient. In this case, it is postulated that enhanced organism virulence might explain the extensive ossicular destruction despite the acute presentation. Interestingly, a study showed that patients with BTM were prone to infection due to impaired phagocytic action and anaemia (19). They are also prone to recurrent upper respiratory tract infections because of generalised lymphoid hyperplasia and expanding marrow of facial bones, which results in nasal obstruction. Patients with diabetes mellitus may present with masked symptoms due to neuropathy. Both patients with

diabetes mellitus developed mastoid abscess with associated complications of meningitis or Bezold's abscess in the absence of otorrhoea symptoms. The immunocompromised condition of these 4 patients could have resulted in the dissemination of infection before any apparent ear symptoms.

Therefore, early adequate treatment of AOM and close vigilant follow-up are important, especially in immunocompromised patients. Antibiotic treatment, however, does not provide absolute protection against the development of complications and, at worst, may mask the symptoms and signs of complications (4,16). Increasing antibiotic resistance behaviours by organisms in biofilms (demonstrated in *Streptococcus pneumoniae* and *Haemophilus influenzae*) may explain why antibiotic treatment does not provide absolute protection (17).

Facial nerve palsy occurred in 4 out of 12 patients in this series; 3 were patients with AOM had facial nerve palsy grade IV to VI (House-Brackmann), which improved after surgery (to grade II at best). The other patient had COM and grade II facial palsy, which had improved to grade I on the second post-operative day. These observations were in contrast to previous studies, which reported total recovery in all AOM patients with facial paralysis (20,21). They were also in contrast to another study, which suggested that facial paralysis in COM had a poor prognosis (22).

A literature review by White and McCans (23) suggested that several potential processes were involved in facial palsy secondary to otitis media: 1) direct involvement of the facial nerve by bacterial invasion, 2) mechanical compression on the vascular supply of the nerve by the purulent exudates or granulation tissue, 3) acute toxic neuritis with venous thrombosis resulting in ischaemia, and 4) bacterial toxins that lead to facial nerve demyelination. More than one of these processes may be involved in the pathophysiology of facial palsy.

Therefore, it is postulated that the recovery of facial nerve function may depend on the underlying pathophysiological processes that resulted in the facial nerve palsy. Recent studies using the results of electrophysiological tests have shown that facial nerve palsy secondary to AOM may be treated clinically (24,25). Another study on facial nerve palsy due to non-cholesteatomatous otitis media also showed good recovery without surgical decompression of the nerve (25,26). However, facial nerve palsy associated with cholesteatoma tends to have a poor prognosis, and mastoid surgery is required to create a safe and dry ear.

Conclusion

Despite the advancements in the treatment of otitis media, mastoid abscess is still a recognised complication in both acute and COM. Although mastoid abscess can occur over a wide age spectrum (3–70 years old), it predominantly occurs in adults. Patients who are immunocompromised have a greater risk of developing mastoid abscesses secondary to AOM. They may also present with vague symptoms, severe disease or other associated complications that require vigilance on the part of the physician. Mastoid abscesses may also develop in immunocompetent patients with COM, especially in association with cholesteatoma. In contrast to previously published data, facial palsy secondary to AOM may not recover completely.

Authors' Contributions

Conception and design: MA

Provision of study materials or patients: GBS, AA

Collection and assembly of data: ZZ

Analysis and interpretation of the data: ZZ

Drafting of the article: MA, ZZ

Critical revision of the article: MA, GBS, AA

Final approval of the article: LS

Correspondence

Dr Mazita Ami

MS (ORL–HNS)

Department of Otorhinolaryngology–Head and Neck Surgery

Faculty of Medicine

Universiti Kebangsaan Malaysia

Jalan Yaacob Latif, Bandar Tun Razak

56000 Kuala Lumpur

Malaysia

Fax: +603- 91737840

E-mail: mazitaami@yahoo.com

References

- Verhoeff M, van der Veen EL, Rovers MM, Sanders EA, Schilder AG. Chronic suppurative otitis media: A review. *Int J Paediatr Otorhinolaryngol*. 2006;**70**(1):1–12.
- Leskinen K. Complications of acute otitis media in children. *Curr Allergy Asthma Rep*. 2005;**5**(4):308–312.
- Leskinen K, Jero J. Acute complications of otitis media in adults. *Clin Otolaryngol*. 2005;**30**(6): 511–516.
- Benito MB, Gorricho BP. Acute mastoiditis: Increase in the incidence and complications. *Int J Paediatr Otorhinolaryngol*. 2007;**71**(7):1007–1011.
- Luntz M, Brodsky A, Nusem S, Kronenberg J, Keren G, Migirov L, et al. Acute mastoiditis—the antibiotic era: A multicenter study. *Int J Paediatr Otorhinolaryngol*. 2001;**57**(1):1–9.
- Lin YS, Lin LC, Lee FP, Lee KJ. The prevalence of chronic otitis media and its complications rates in teenagers and adults. *Otolaryngol Head & Neck Surg*. 2009;**140**(2):165–170.
- Lasisi AO, Olaniyan FA, Muibi SA, Azeez IA, Abdulwasiiu KG, Lasisi TJ, et al. Clinical and demographic risk factors associated with chronic suppurative otitis media. *Int J Paediatr Otorhinolaryngol*. 2007;**71**(10):1549–1554.
- Tamir S, Shwartz Y, Peleg U, Shaul C, Perez R, Sichel JY. Shifting trends: Mastoiditis from a surgical to a medical disease. *Am J Otolaryngol*. 2010;**31**(6):467–471.
- Migirov L, Yakirevitch A, Kronenberg J. Mastoid subperiosteal abscess: A review of 51 cases. *Int J Paediatr Otorhinolaryngol*. 2005;**69**(11):1529–1533.
- Bauer PW, Brown KR, Jones DT. Mastoid subperiosteal abscess management in children. *Int J Paediatr Otorhinolaryngol*. 2002;**63**(3):185–188.
- Al-Serhani AM. Mastoid abscess: Underlying disease and management. *Am J Otol*. 1996;**17**(5):694–696.
- Pang HYL, Barakate MS, Havas T. Mastoiditis in a paediatric population: A review of 11 years experience in management. *Int J Paediatr Otorhinolaryngol*. 2009;**73**(11):1520–1524.
- Mustafa A, Heta A, Kastrati B, Dreshaj Sh. Complications of chronic otitis media with cholesteatoma during a 10-year period in Kosovo. *Eur Arch Otorhinolaryngol*. 2008;**265**(12):1477–1482.
- Penido Nde O, Borin A, Iha LCN, Suguri VM, Onishi E, Fukuda Y, et al. Intracranial complications of otitis media: 15 years experience in 33 patients. *Otolaryngol Head Neck Surg*. 2005;**132**(1):37–42.
- Kangsanarak J, Navacharoen N, Foonant S, Ruckphaopunt K. Intracranial complications of suppurative otitis media: 13 years' experience. *Am J Otol*. 1995;**16**(1):104–109.
- Dhooge IJM, Albers FWJ, Van Cauwenberge PB. Intratemporal and intracranial complications of acute suppurative otitis media in children: Renewed interest. *Int J Paediatr Otorhinolaryngol*. 1999; **49 Suppl 1**:S109–S114.
- Vergison A. Microbiology of otitis media: A moving target. *Vaccine*. 2008;**26 Suppl 7**:G5–G10.
- Almadori G, Ninno MD, Cadoni G, Di Mario A, Ottaviani F. Facial nerve paralysis in acute otomastoiditis as presenting symptom of FAB M2, T8;21 leukemic relapse. Case report and review of the literature. *Int J Paediatr Otorhinolaryngol*. 1996;**36**(1):45–52.

19. Wanachiwanawin W. Infections in E-beta Thalassemia. *J Pediatr Hematol Oncol.* 2000;**22(6)**:581-587.
20. Zinis LOR, Gamba P, Balzanelli C. Acute Otitis Media and Facial Nerve Paralysis in Adults. *Otol Neurotol.* 2003;**24(1)**:113-117.
21. Leskinen K, Jero J. Complications of acute otitis media in children in Southern Finland. *Int J Paediatr Otorhinolaryngol.* 2004;**68(3)**:317-324.
22. Yetiser S, Tosun F, Kazkayasi M. Facial Nerve Paralysis Due to Chronic Otitis Media. *Otol Neurotol.* 2002;**23(4)**:580-588.
23. White N, McCans KM. Facial paralysis secondary to acute otitis media. *Pediatr Emerg Care.* 2000;**16(5)**:343-345.
24. Yonamine FK, Tuma J, Silva RF, Soares MC, Testa JR. Facial paralysis associated with acute otitis media. *Braz J Otorhinolaryngol.* 2009;**75(2)**:228-230.
25. Makeham TP, Croxson GR, Coulson S. Infective causes of facial nerve paralysis. *Otol Neurotol.* 2007;**28(1)**:100-103.
26. Ozbek C, Somuk T, Ciftçi O, Ozdem C. Management of facial nerve paralysis in noncholesteatomatous chronic otitis media. *B-ENT.* 2009;**5(2)**:73-77.