

Anuradha Calicut KINI RAO, Bhavna NAYAL

Submitted: 9 Jul 2012
Accepted: 8 Aug 2012

Department of Pathology, Kasturba Medical College Manipal University,
Madhav Nagar, 576104 Manipal, India

Abstract

Ocular myxomas are rare neoplasms. We report a case of conjunctival myxoma in a 33-year-old male. Clinically, it was diagnosed as a conjunctival cyst. Histopathological findings revealed spindle, and fusiform cells in loose myxoid stroma with cystic change. There were no systemic abnormalities detected.

Keywords: benign, conjunctival, neoplasm, myxoma, ocular

Introduction

Myxoma, derived from the primitive mesenchyme, is a benign soft tissue tumor (1). It is considered to be the most common tumor of the heart, although it can also arise in bone, skin, skeletal muscle, the genitourinary system, the gastrointestinal tract, and nasal sinuses. Myxomas can occur as localized disease or as components of Carney complex, Mazabraud syndrome, and McCune-Albright syndrome. Ocular myxomas are rare and known to differ clinically and histopathologically from extraocular myxomas (2,3). Clinically, conjunctival myxomas can be mistaken for amelanotic nevus, amelanotic melanoma, squamous cell carcinoma, lipoma, and cyst. We report a patient presenting with a translucent swelling in the left eye that was diagnosed as conjunctival myxoma on histopathological examination.

Case report

A 33-year-old male presented with a gradually progressing painless swelling in the nasal bulbar conjunctiva of his left eye that had been present for year. There was redness of the left eye, but there was no associated pain or discharge. The patient had no cardiac, endocrine, or cutaneous abnormalities. There were no other visual symptoms or a history of preceding trauma. His ophthalmological examination was unremarkable. A slit-lamp examination of the left eye revealed a well-circumscribed cystic mass measuring 8.5 mm × 8.5 mm in the nasal bulbar conjunctiva with a clinical diagnosis of conjunctival cyst. The lesion was completely excised under local anesthesia. Histopathological examination revealed loose myxoid stroma with spindle and

fusiform cells, showing intracytoplasmic and intranuclear inclusions, a few giant cells, and mast cells (Figure 1 and 2). A small corrugated cyst devoid of lining epithelium with hyalinized wall surrounded by neutrophils and lymphocytes was also seen (Figure 3). Histopathological diagnosis of conjunctival myxoma with cystic change was given. However, the patient was lost to follow up.

Discussion

Conjunctival myxoma is a rare ocular lesion. The first case reported was by Magalif in 1913 (4). In studies by Grossniklaus and Shields, conjunctival myxomas accounted for 0.002% and < 0.001% of all conjunctival lesions, respectively

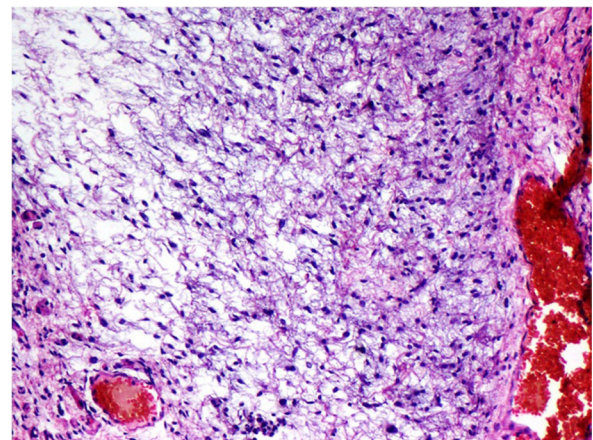


Figure 1: Conjunctival myxoma. Loose myxoid stroma containing spindle and fusiform cells (hematoxylin-eosin, 200× magnification).

(5,6). To our knowledge, only 29 cases of this lesion have been published in the literature. This tumor is usually seen in adults and has no sex predilection(2).

Conjunctival myxomas are well-circumscribed, yellow-pink, translucent cystic or solid masses with dimensions ranging from 4 to 16 mm (2). This case had a similar presentation, with the mass measuring 8.5 mm in diameter.

Histopathologically, conjunctival myxomas consist of scattered stellate and spindle-shaped cells with intracytoplasmic and intranuclear vacuoles in a hyaluronic acid-rich mucinous matrix with sparse vascular structures, and reticulin fibers (3). Similar histopathological

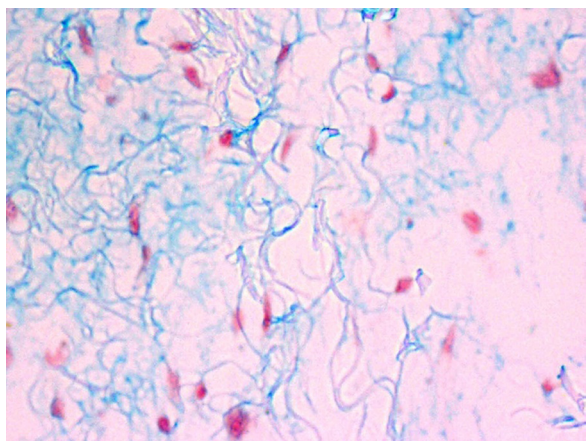


Figure 2: Conjunctival myxoma with abundant mucoid material confirmed by Alcian blue positivity (Alcian blue, 400× magnification).

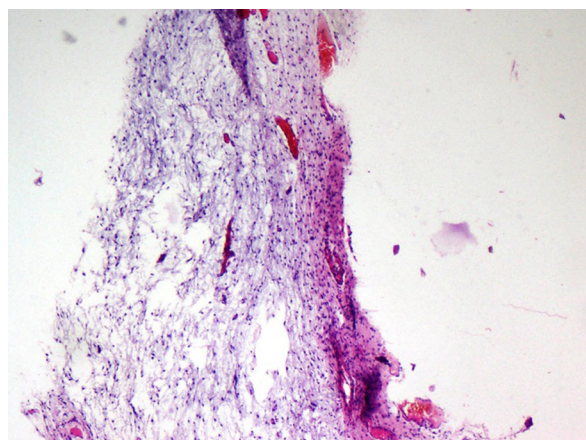


Figure 3: Cystic change in conjunctival myxoma (haematoxylin-eosin, 40× magnification).

features were observed in our case, along with a cyst-like cavity and mast cells. The presence of cystic cavities and mast cells make conjunctival myxomas distinct from non-ocular soft tissue myxomas (2).

Conjunctival myxomas should be differentiated from various other conjunctival lesions, including benign lesions such as amelanotic nevus, cyst, lymphangioma, myxoid chondroma, myxoid neurofibroma, spindle cell lipoma, and malignant lesions like amelanotic melanoma, botryoid-type rhabdomyosarcoma, myxoid chondrosarcoma, myxoid malignant fibrous histiocytoma, and myxoid liposarcoma (6,7). Clinically, well-circumscribed borders, an absence of recurrence and histological absence of pigmentation, sparse vascular structures, and cellular morphology help in differentiating conjunctival myxomas from these lesions (2,7). Conjunctival myxomas are treated by complete excision, as in the present case. Recurrences are known to be a rarity (2,7). Myxomas may also exist as a component of various other syndromes with coexisting skin, bone, and endocrine abnormalities that require a thorough detailed clinical examination and investigation (3).

Conclusion

In conclusion, conjunctival myxomas are rare ocular lesions with several clinical mimics that require excision for confirmation and treatment. Furthermore, they can herald the existence of a hitherto undetected syndrome complex, prompting a thorough investigation.

Authors' Contributions

Conception and design, critical revision of the article for the important intellectual content, and final approval of the article: ACKR
Analysis and interpretation of the data and drafting of the article: BN

Correspondence

Professor Dr Anuradha Calicut Kini Rao
MBBS (SMC, Madras), MD (KMC, Manipal),
DNB (New Delhi)
Department of Pathology
Kasturba Medical College Manipal University
Madhav Nagar
576104 Manipal, India
Tel: +9182 0292 2492
Fax: +9182 0257 1927
Email: anuchenna@yahoo.com

References

1. Stout AP. Myxoma, the tumor of primitive mesenchyme. *Ann Surg.* 1948;**127(4)**:706–719.
2. Chen CL, Tai MC, Chen JT, Chen CH, Jin JS, Lu DW. A rare case of conjunctival myxoma and a review of literature. *Ophthalmologica.* 2008;**222(2)**:136–139.
3. Demirci H, Shields CL, Eagle RC, Shields JA. Report of a conjunctival myxoma case and review of the literature. *Arch Ophthalmol.* 2006;**124(5)**:735–738. Magalif.
4. Myxoma conjunctivae. *Klin Monatsbl Augenheilkd.* 1913;**51**:844.
5. Grossniklaus HE, Green WR, Luckenbach M, Chan CC. Conjunctival lesions in adults. A clinical and histopathologic review. *Cornea.* 1987;**6(2)**:78–116.
6. Shields CL, Demirci H, Karatza EC, Shields JA. Clinical survey of 1,643 melanocytic and nonmelanocytic conjunctival tumors. *Ophthalmology.* 2004;**111(9)**:1747–1754.
7. Kilic A, Kösem M, Demirok A, Cinal A, Yasar T. Conjunctival myxoma: A clinicopathologic report. *Ophthalmic Surg Lasers Imaging.* 2008;**39(6)**: 514–516.