

Imprint Cytological Diagnosis of Colonic Adenocarcinoma Metastatic to Liver

Shashikant ADLEKHA¹, Tandra CHADHA², Prasad KRISHNAN³,
B SUMANGALA¹

Submitted: 14 Jul 2012

Accepted: 26 Aug 2012

¹ Department of Pathology, Sree Narayana Institute of Medical Sciences, Ernakulam-683594, Kerala, India

² Department of Microbiology, Sree Narayana Institute of Medical Sciences, Ernakulam-683594, Kerala, India

³ Department of Surgery, Sree Narayana Institute of Medical Sciences, Ernakulam-683594, Kerala, India

Abstract

The liver is a common visceral site for metastatic tumours. Radiological features of the liver, fine needle aspiration cytology (FNAC) and histopathological evaluation (HPE) of liver nodules have a significant role in pre-operative diagnosis of liver lesions. In an intraoperative setting, frozen section biopsy plays a major diagnostic modality but the role of imprint cytology of liver nodules is also appealing. Imprint cytology is a valuable and precise tool in diagnosing the lesions for a rapid intraoperative diagnosis. This study presents a case of colorectal cancer liver metastasis diagnosed by imprint cytology intraoperatively.

Keywords: cytology, frozen section, imprint, intraoperative, liver, metastasis

Case Report

A 28 years old female presented with abdominal pain and chronic diarrhoea. Subsequently, she underwent a full length colonoscopy which showed multiple polyps studded in the entire colon with a large polypoidal lesion about 5 cm from the anal verge. A colonoscopic biopsy of the lower end lesion was suggestive of tubulovillous adenoma of colorectum with moderate dysplasia. She was diagnosed with a case of polyposis colon. There was no family history of polyposis colon or colonic malignancy. She underwent routine blood investigation and a contrast enhanced computed tomography (CT) scan of the abdomen. There was no evidence of metastasis and she was taken up for surgery.

Intraoperatively there was a 5 mm lesion detected in the left lobe of the liver. A non-anatomical resection of the lesion was done. Imprint cytology smears were prepared by gentle touch (no gliding movement, so as to prevent distortion of cell shape and morphology) on the liver nodule, fixed in 95% ethyl alcohol for 6 seconds and stained with rapid hematoxylin and eosin (H&E) stain (Source: BIOLAB

DIAGNOSTICS, INDIA- 3 minutes staining of H&E with no need of decolourisation and results comparable with conventional H&E staining) and papanicolaou (PAP) stain, the liver nodule was then processed for histopathological evaluation. The imprint cytology showed few clusters of elongated tumour cells with hyperchromatic dark nuclei amidst the background of benign hepatocytes (Figure 1) and was reported as metastatic adenocarcinoma, which was confirmed by the histopathological examination of the nodule (Figure 2). The patient underwent a total proctocolectomy with end ileostomy. The total proctocolectomy specimen showed a large number (> 100) of sessile and pedunculated polyps carpeting the specimen (Figure 3). The histopathological examination of the resected specimen revealed moderately differentiated adenocarcinoma of rectum with infiltration up to the serosa. Vascular and lymphatic invasion were seen and 1 out of 15 pericolic lymph nodes isolated, showed metastatic adenocarcinoma. Due to poor patient compliance genetic studies could not be performed.

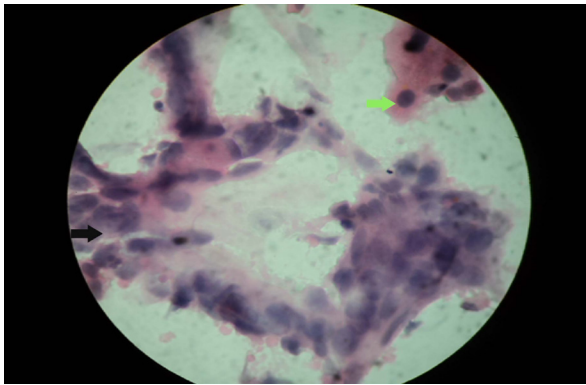


Figure 1: Smear showing cluster of atypical columnar cells (black arrow) with adjacent benign hepatocytes (green arrow)-Haematoxylin and Eosin, 400× magnification.

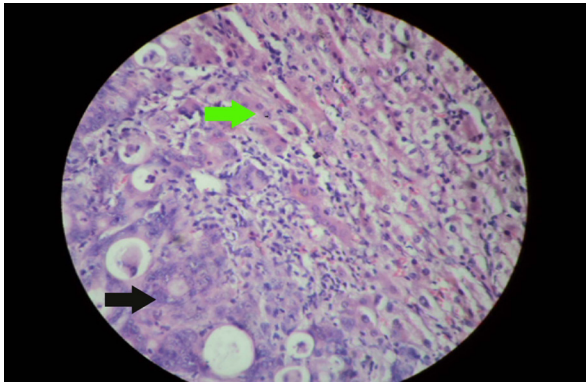


Figure 2: Section showing malignant tumour glands (black arrow) infiltrating the liver parenchyma (green arrow)-Haematoxylin and Eosin, 400× magnification.

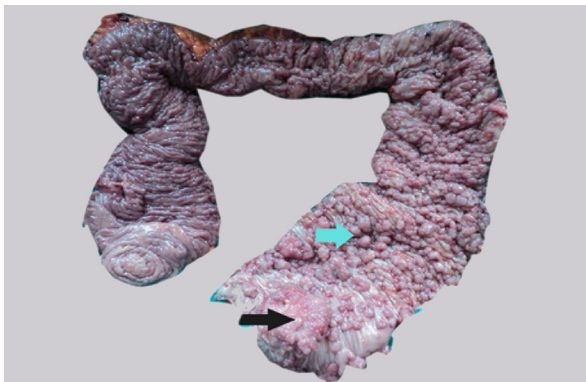

Figure 3: Specimen showing an ulceroproliferative lesion (black arrow) and multiple polyps (green arrow).

Discussion

The liver is one of the most common sites of metastatic disease, accounting for 25% of the metastasis to solid organ (1). The colon is the second most common source of metastatic carcinoma to liver, accounting for 15.7% of hepatic metastasis (2). Crushed and imprint smears can be used in adjunct with core needle biopsy for immediate assessment of histological liver lesions. It has been previously documented by Sherlock et al. (3), Grossman et al. (4), and Carney et al. (5), that cytological evaluation of residual debris accompanying large core needle biopsies increases the diagnostic yield in malignant diseases in comparison with histological evaluation. Cytological and histological studies of liver biopsies are complementary and use of both the methods can increase the diagnostic sensitivity as documented by Bell et al. (6), and Dusenbery et al., (7).

Adenocarcinomas are the most frequent type of neoplasm presenting as carcinoma of unknown primary (CUP) in the liver of adult oncology patients (8). A cytological diagnosis of colonic metastatic adenocarcinoma is supported by viewing linear strips of columnar cells with elongated nuclei and ruby red nucleoli in a necrotic background. The differential diagnosis of metastatic colonic adenocarcinoma includes metastatic adenocarcinoma from various other organs like breast, lung, stomach, gall bladder, pancreas etc. The exact source of metastatic carcinoma has to be diagnosed by complementary ancillary techniques. There are many centres where frozen section facilities may not be available. In such institutions imprint cytology may help the surgeons to get immediate intraoperative diagnosis and help to modify their management. Imprint cytology can also be used as a complementary diagnostic tool for frozen section in advanced centres, where such facilities are available. In this case, imprint cytology helped to prognosticate the advanced nature of the disease.

Conclusion

Colonic adenocarcinoma is a frequent source of metastasis to liver. Apart from fine needle aspiration cytology, crush and touch smears of the liver core are also important adjunct and complementary tools in the diagnosis of metastatic adenocarcinoma. Imprint cytology is a cost effective diagnostic tool and an additional

advantage to the centres where frozen section is not available.

Acknowledgement

None.

Conflict of Interest

None.

Fund(s)

None.

Authors' Contributions

Conception and design, drafting of the article, final approval of the article, and administrative, technical or logistic support: SA, TC, PK, BS
Critical revision of the article for the important intellectual content: D
Provision of study materials or patient: SA, TC, PK

Correspondence

Dr Shashikant Adlekha
MD Pathology (Jabalpur, India), DNB Pathology (National Board, India)
Department of Pathology
Sree Narayana Medical College
North Kuthiyatode
Chalakkal-683594
Ernakulam
Kerala, India
Tel: 917293052109
Fax: 914842479199
Email: shuntyad@yahoo.co.in

References

1. Abbruzzese JL, Abbruzzese MC, Lenzi R, Hess KR, Raber MN. Analysis of a diagnostic strategy for patients with suspected tumours of unknown origin. *J clin oncol.* 1995;**13(8)**:2094–2103.
2. Craig JR, Peter RL, Edmonson HA. Tumors of the liver and intrahepatic bile ducts. In: *Atlas of tumor pathology*, 26 fasc, ser 2. Washington (DC): AFIP; 1989. p. 171–179.
3. Sherlock P, Kim YS, Koss LG. Cytological diagnosis of cancer from aspirated material obtained at liver biopsy. *Am J Dig Dis.* 1967;**12(4)**:396–402.
4. Grossman E, Goldstein MJ, Koss LG, Winawer SJ, Sherlock P. Cytological examination as an adjunct to liver biopsy in the diagnosis of hepatic metastases. *Gastroenterology.* 1972;**62(1)**:56–60.
5. Carney CN. Clinical cytology of the liver. *Acta Cytol.* 1975;**19(3)**:244–250.
6. Bell DA, Carr CP, Szyfelbein WM. Fine needle aspiration of cytology of focal liver lesions: Results obtained with examination of both cytological and histological preparations. *Acta Cytol.* 1986;**30(4)**:397–402.
7. Dusenbery D, Ferris JV, Thaete FL, Carr BI. Percutaneous ultrasound guided needle biopsy of hepatic mass lesions using a cytohistological approach: Comparison of two needle types. *Am J Clin Pathol.* 1995;**104(5)**:583–587.
8. Pavlidis N, Fizazi K. Cancer of unknown primary (CUP). *Crit Rev Oncol Hematol.* 2005;**54(3)**:243–250.