

Rajendra Kumar GHRITLAHAREY

Submitted: 29 Aug 2012

Accepted: 27 Nov 2012

Department of Paediatric Surgery, Gandhi Medical College and Associated Kamla Nehru and Hamidia Hospitals Bhopal, Madhya Pradesh 462001, India

Abstract

This is a case report of a 10-year-old boy who presented with features of acute intestinal obstruction. Clinical examination revealed distended abdomen, visible bowel loops, and a lump in the right upper quadrant of the abdomen. Clinically, the diagnosis of intussusception was suspected and confirmed on sonography examination. Exploration of the abdomen revealed ileo-colic intussusception. Manual reduction of intussusception was possible except the last part that had an intraluminal solitary polyp (3 × 4 cm) occupying the 3/4th of the lumen of the terminal ileum. Segmental resection of the ileum containing polyp was done, and the ileal continuity was restored with ileo-ileal anastomosis. His post-operative recovery was uneventful. Histologically, it was consistent with the inflammatory intestinal polyp without any evidence of malignancy.

Keywords: children, intestinal polyp, intestinal obstruction, intussusception

Introduction

Intussusception is derived from the Latin words “*intus*” (within) and “*suscipere*” (to receive). Intussusception is the invagination of one part of the intestine into another (1). Intussusception remains a common cause of bowel obstruction in infants and young children and results in significant morbidity and mortality, if not promptly treated (2–4). The primary type (idiopathic) is mostly seen during infancy in about 95% of cases. In older children, intussusception occurs usually due to secondary identifiable causes, either intraluminal or intramural pathologies such as Meckel’s diverticulum, ileal polyp, appendiceal stump, lipoma, duplication of ileum, malignancies, etc. (1,3). The pathological lead points (PLP) causing intussusception in infants and young children is reported in about 1.5–14% of the cases and tends to increase with age (1,3,4). Intussusception caused by ileal polyp as a lead point is rare and generally reported as case reports in the literature (1). Herein, report a 10-year-old boy with a solitary large intraluminal ileal polyp presenting as an intussusception. He was successfully managed with segmental resection of the ileum containing polyp and ileo-ileal anastomosis.

Case report

A 10-year-old boy was admitted with complaints of acute intestinal obstruction of

three days duration. He had a history of recurrent abdominal pain for six months without lower gastrointestinal bleeding or melaena. There was no history of passing worms in stool. His abdominal examination revealed visible bowel loops (Figure 1). A tender lump was also palpable in the right upper quadrant of the abdomen. Rectal digital examination revealed as empty, no blood or mucus on examining finger. Other systemic examinations were within normal limits. Standing skiagram of the abdomen showed multiple air fluid levels without gas under the diaphragm. Ultrasonography (USG) of the abdomen suggestive of intussusception with dilated bowel loops, although PLP was not mentioned. Exploratory laparotomy revealed an ileo-colic intussusception. Manual reduction was done, and all parts were successfully reduced except the ileum containing the polyp (Figure 2a, 2b). Segmental resection of the ileum containing the solitary large polyp (3 × 4 cm) was done, and the ileal continuity was restored with ileo-ileal anastomosis. The polyp (Figure 3) was not pedunculated, it occupied about 3/4th of the lumen of the ileum, and was about one foot proximal to the ileocecal region. The rest of the viscera were normal, and there was no mesenteric lymphadenopathy. His post-operative recovery was uneventful. Histologically, it reveals intestinal tissues with polypoidal mass lined with inflammatory granulation tissues with moderate stromal edema with chronic

inflammatory infiltrate constituting lymphocytes and plasma. The above histopathological findings are consistent with intestinal polyp (inflammatory type) without any evidence of malignancy (Figure 4).

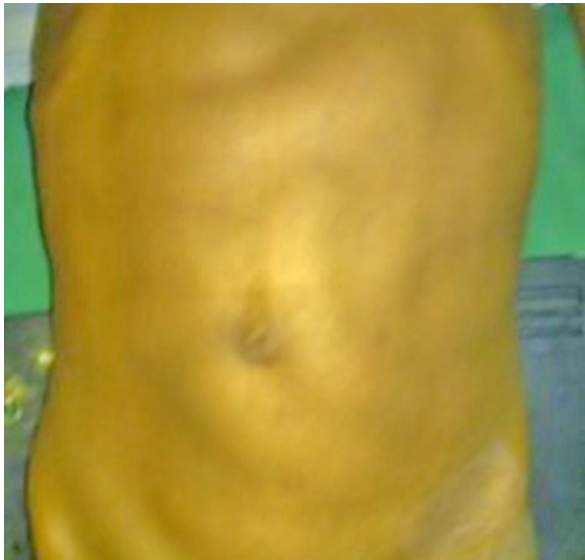

Figure 1: Clinical photograph: showing visible bowel loops (intestinal obstruction).

Discussion

Intussusception has been reported to occur more in male children than female (1,2,5,6). Approximately 75% of it occurs within the first

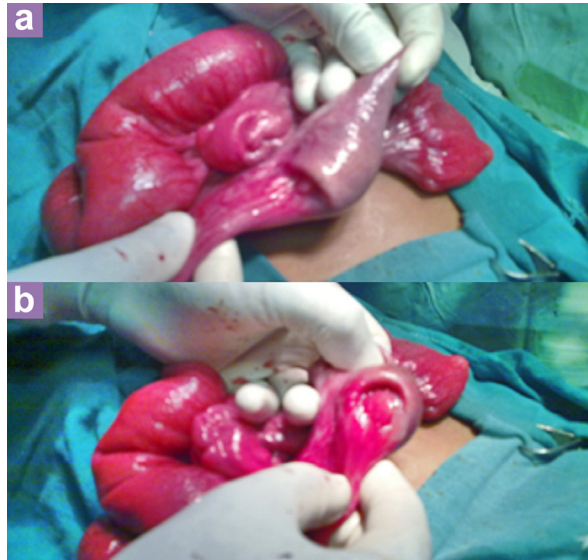


Figure 2: (a) Operative photograph: showing partially reduced intussusceptions; (b) Operative photograph: showing intraluminal mass (polyp) as lead point.

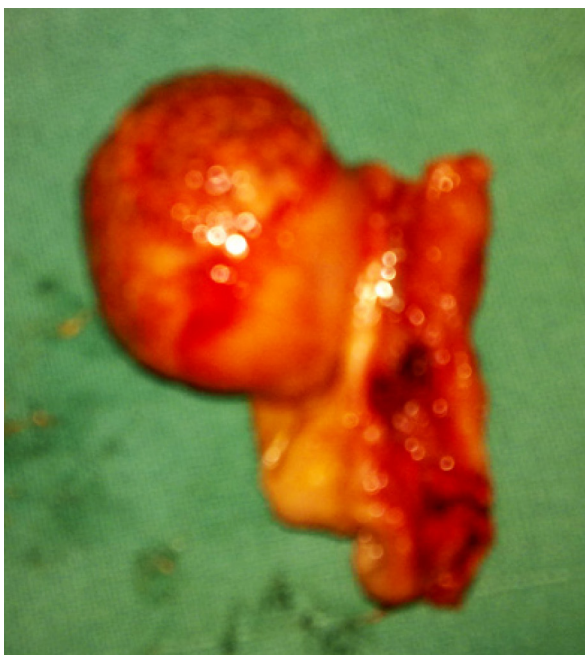

Figure 3: Ileal polyp (resected specimen).

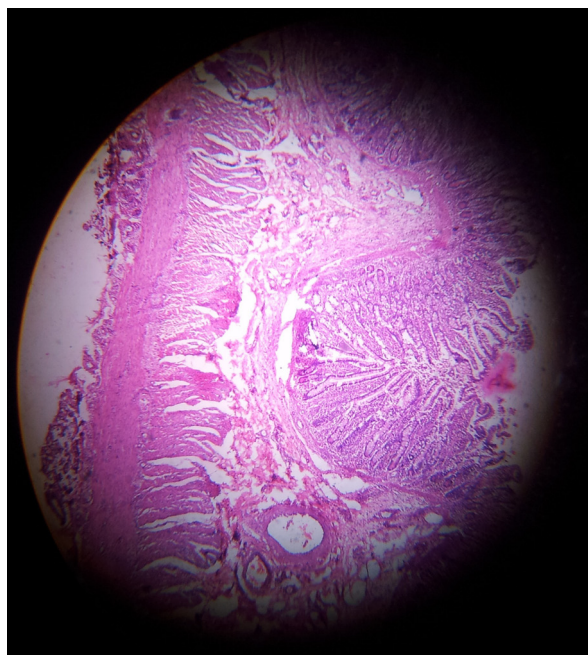


Figure 4: Histopathology of excised ileal polyp: findings consistent with inflammatory ileal polyp.

two years of life, and more than 40% are seen between 3–9 months of age (1–3). A combination of abdominal pain, abdominal mass and rectal bleeding/mucoid stools (classical triad of symptoms of intussusception) are reported to occur in 30–65% of cases (1,3,5,6). In primary (idiopathic) intussusception, where no PLP is identified, are mostly due to thickened bowel wall lymphoid tissues (Peyer's patches)/non-specific mesenteric lymphadenitis (1,3). The PLP causing the intussusception is reported to occur in about 1.5–14% of the cases and tends to increase with age (1,3,4). Intussusception caused by identifiable causes (PLP) is mostly reported as case reports in the literature (1). An intussusception caused by an ileal polyp as a lead point is rare in children. In a review of 188 case reports (published in between 1998–2004) on intussusceptions caused by PLPs, there were only 17 cases of intussusceptions where the lead points were polyp (1).

Currently, the diagnosis of intussusception is usually suspected clinically and confirmed on USG of the abdomen. For acute cases only investigations needed are skiagram and USG of the abdomen (7). CT scans of the abdomen add little in the emergency cases. On USG, if a complex mass is present in the centre of the intussusception in both transverse and longitudinal sections, there is a possibility of a lead point/secondary cause for it (8). Cases of ileal polyps in children presenting as recurrent abdominal pain or lower gastrointestinal bleeding may be investigated by capsule endoscopy/balloon enteroscopy, if available (9,10).

The delay in the diagnosis of intussusception leads to increased chances of bowel gangrene and the need for bowel resection and thereby increasing the morbidity and mortality as well. The interval between the onset of symptoms and institution of the treatment is of paramount importance. It is therefore very important for the treating medical personnel to diagnose the case of intussusception in its early phase and should institute an effective therapy (medical/surgical) to reduce the morbidity and mortality (1–3,6).

In general, the treatment options for the intussusception are hydrostatic, air enema or barium reduction, exploratory laparotomy (manual reduction, segmental bowel resection for gangrene and anastomosis, hemicolectomy, creation of stoma, etc.) and laparoscopic procedures (1–7,11,12). Non-operative treatment involves an initial confirmation of diagnosis of intussusception, either with USG or barium enema (excluding peritonitis and gangrene of the intestine) and followed by the pressure reduction with barium, saline enema, or air enema under

image guidance. Non-operative management has been shown to shorten hospitalisation and reduce morbidity and mortality (1). Presence of the bowel gangrene and peritonitis warrants surgical management for intussusception. Surgical management consists of either of one; manual reduction, segmental bowel resection for gangrene and anastomosis, hemicolectomy, creation of stoma (1–7,12). The presence of lead points during the investigation for intussusception on USG or barium enema warrants surgical management of the case. The size of the polyp is usually smaller than 5 cm, although sizes up to 20 cm has also been reported (12). In the present case, the diagnosis of intussusception was confirmed on USG, and ileal polyp as a lead point for it was not detected pre-operatively. At present, laparoscopy is not being done in the department, so exploratory laparotomy was done and the ileal polyp forming the lead point was detected and treated by segmental resection of the involved distal ileum with ileo-ileal anastomosis.

Conclusion

In conclusion, in older children and adults, intussusception occurs usually due to secondary identifiable causes, either intraluminal or intramural. Intussusception originating from PLPs remains a diagnostic challenge, and it may not be possible to diagnose pre-operatively in all the cases. Surgery remains the mainstay of treatment for an intussusception caused by PLPs.

Acknowledgement

None.

Conflicts of Interest

None.

Funds

None.

Correspondence

Dr Rajendra K Ghritlaharey
MBBS, MS (Indore, India), MCh (Bhopal, India), FAIS, MAMS
Department of Paediatric Surgery
Gandhi Medical College and Associated Kamla Nehru and Hamidia Hospitals Bhopal
Madhya Pradesh 462 001, India
Tel: + 91-755 405 0571
Email: drrajendraki@rediffmail.com

Reference

1. Ein SH, Daneman A. Intussusception. In: Grosfeld JL, O'Neill JA, Coran AG, Fonkalsrud EW, editors. *Pediatric Surgery*. 6th ed. Pennsylvania (PA): Mosby Elsevier; 2006. p. 1313–1341.
2. Ghritlaharey RK, Budhwani KS, Shrivastava DK. Exploratory laparotomy for acute intestinal conditions in children: A review of 10 years of experience with 334 cases. *Afr J Paediatr Surg*. 2011;**8(1)**:62–9. doi: 10.4103/0189-6725.78671.
3. Bode CO. Presentation and management outcome of childhood intussusception in Lagos: A prospective study. *Afr J Paediatr Surg*. 2008;**5(1)**:24–28. doi: 10.4103/0189-6725.41632.
4. Kaiser AD, Applegate KE, Ladd AP. Current success in the treatment of intussusception in children. *Surgery*. 2007;**142(4)**:469–477.
5. Saleem MM, Al-Momani H, Abu Khalaf M. Intussusception: Jordan University Hospital experience. *Hepatogastroenterology*. 2008;**55(85)**: 1356–1359.
6. Ugwu BT, Legbo JN, Dakum NK, Yiltok SJ, Mbah N, Uba FA. Childhood intussusception: a 9-year review. *Ann Trop Paediatr*. 2000;**20(2)**:131–135.
7. Peh WC, Khong PL, Lam C, Chan KL, Saing H, Cheng W, et al. Ileoileocolic intussusception in children: diagnosis and significance. *Br J Radiol*. 1997;**70(837)**:891–896.
8. Lam AH, Firman K. Ultrasound of intussusception with lead points. *Australas Radiol*. 1991;**35(4)**:343–345.
9. Fritscher-Ravens A, Scherbakov P, Bufler P, Torroni F, Ruuska T, Nuutinen H, et al. The feasibility of wireless capsule endoscopy in detecting small intestinal pathology in children under the age of 8 years: a multicentre European study. *Gut*. 2009;**58(11)**:1467–1472. doi: 10.1136/gut.2009.177774.
10. Huang Y, Shao CH, Leung YK. Application of double balloon enteroscopy in pediatric patients. *Zhonghua Er Ke Za Zhi*. 2010;**48(8)**:599–602.
11. Bonnard A, Demarche M, Dimitriu C, Podevin G, Varlet F, François M, et al. Indications for laparoscopy in the management of intussusception: A multicenter retrospective study conducted by the French Study Group for Pediatric Laparoscopy (GECI). *J Pediatr Surg*. 2008;**43(7)**:1249–1253. doi: 10.1016/j.jpedsurg.2007.11.022.
12. Akbulut S, Sevinc MM, Cakabay B, Bakir S, Senol A. Giant inflammatory fibroid polyp of ileum causing intussusception: a case report. *Cases J*. 2009;**2**:8616. doi: 10.4076/1757-1626-2-8616.s.