

Peritonsillar Abscess in Northern Nigeria: A 7 Years Review

Olushola Abdulrahman AFOLABI¹, Alli ABDULLAHI², Abimiku Soloman LABARAN², Saadat LADAN², Rashidat SANNI², Emmanuel MUSA², Babagana Mohammad AHMAD²

Submitted: 8 Mar 2014
Accepted: 20 Jul 2014

¹ Department of Ear, Nose and Throat, University of Ilorin/University of Ilorin Teaching Hospital, 2400, Ilorin, Nigeria

² National Ear Care Center Independence/Golf Course Way, Kaduna, Nigeria

Abstract

Background: The aim of this study was to describe the clinico-epidemiologic profile of peritonsillar abscess (PA) seen in our center in northern Nigeria.

Methods: This was a retrospective review of all patients with PA managed in our hospital over a 7-year period. Case notes were reviewed and information retrieved included biodata and clinical information were entered into an SPSS statistical software version 20.0 and analysed descriptively and result presented in table and figures.

Results: A total of 25 patients were seen during the study period age ranged from 2–52 years with a mean age of 25.96 years; 14.1 (SD 2.8). Male to female ratio of $\approx 1.1:1.0$. Right side was affected in 60%. The period of presentation of patients with PA varied between 4–12 days with a mean duration of 6.5 days. The presenting complaints in these patients varied from sore throat alone in 4 (16%), fever and sore throat in 17 (68%), others 16%. The duration of hospital stay varied from between 1 to 8 days with mean of 4.2 days; 3.32 days (SD 1.1). All the patients had incision and drainage with no recurrence of symptoms.

Conclusion: PA is an Ear, Nose and Throat emergency that is commoner amongst the young adult males and the modality of treatment is still incision and drainage in our setting.

Keywords: emergency, peritonsillar abscess, incision, drainage, antibiotic, sore throat

Introduction

Peritonsillar abscess (PA) is one of the common otolaryngological emergency (1) and patients usually have a classical presentation of odynophagia and dysphagia, fever, a characteristic hot potato speech and trismus. Clinical assessment of the oropharynx shows marked asymmetry of the both peritonsillar area with oedema and erythema with displacement of the uvula to the contralateral side (1).

PA is considered a suppurative complication of an acute tonsillitis with penetration of the tonsillar capsule by infectious organism and it is usually treated with incision and drainage under an antibiotics coverage. PA may also be seen among in-patients with no previous history of tonsillitis and when there is no evidence of concurrent tonsillitis (2). The incidence of tonsillitis peaks in childhood and are most common among the young adults. Most cases were reported among older children, adolescents, and young adults (2).

PA is one of the most commonly occurring

acute suppurative infections of the head and neck in young adults and children. This infection do affect age groups, but the highest incidence is found among adults 20 to 40 years of age (3,4). PA is almost always first encountered by the family physician, and those with appropriate training and experience can diagnose and treat most patients at this level. Prompt recognition and initiation of therapy is important to avoid potential serious complications. Epidemiology of PA has not been vastly discussed in the literature. Although its yearly incidence in the United States from previous research was estimated at 1 in 6500, in Northern Ireland, it was reported as 1 per 10 000 patients per year, with an average age of 26.4 years (5), however to our knowledge no data is available for a developing country like Nigeria. In addition, previous literatures have revealed an alteration in the causative bacteria from gram-positive cocci (mainly Streptococcus β -hemolytic group A) to anaerobes and gram-negative rods (6).

A recent study reported an increased incidence along with a more aggressive presentation of PA among the pediatric population (7). The aim of the study is to describe the clinic-epidemiologic profile of PA which is one of the deep neck space infections seen in our center in northern Nigeria.

Methods

This was a retrospective study of all patients with clinical diagnosis of PA (International Classification of Diseases 9 [ICD9] code 475), hospitalised and treated between January 2005 and December 2011 at the National Ear Care Center which is the only specialised center for the care of ear, nose and throat diseases located in northern Nigeria. The work was approved by the ethical review committee of the hospital. The case notes were retrospectively reviewed and information retrieved included age, sex, duration of symptoms, abscess location, clinical presentation, and symptoms of presentation, examination findings, prior antibiotic therapy, and hospital stay. Also retrieved were history of recurrent tonsillitis, previous PA, culture results, co-morbidities and complications. Incision and drainage were performed for all patients with PA, usually after the diagnosis. All this data were entered into SPSS version 20.0 statistical software and analysed descriptively and data presented in tables and figures.

Results

A total of 31 patients presented with PA however only 25 patients had complete data for analysis and fit into the inclusion criteria for the study (N = 25). The age range from 2–52 years with a mean age of 25.96 years (SD = 14.1 ± 2.8), median age of 24.00 (Figure 1). The modal presentation was found among those 10 years and above for both sexes. There were 13 (52%) males and 12 (48%) females with male to female ratio of ≈ 1.1:1.0.

A total of 15 (60%) patients had the PA on the right side while 9 (36%) had the PA on the left side and only 1 (4%) patient had bilateral PA (Figure 2).

The duration of presentation of patients with PA varied between 4–12 days from our study with a mean duration of 6.5 days; 2.31 (SD 0.46) (Table 1). Age to duration of symptom cross-tabulation before showed early presentation among the younger age group than the older age group with 72% presenting within a week of onset (Table 1). The presenting complaint of patients varied from

sorethroat alone in 4 (16%), fever and sorethroat in 17 (68%), fever, sorethroat and dysphagia in 3 (12%) and dysphagia alone in 1 (4%). Upon arrival, patients were questioned about their symptoms, fever was found in 21 (84%), odynophagia in 25 (100%), oral intake difficulties 18 (72%), muffled voice “Hot potato” speech found in all the patients 25 (100%) (Table 2). Only 4 (16%) had a positive history of diabetes mellitus among the 25 patients that satisfied the criteria and none had history of foreign body in the throat prior to presentation, referred ipsilateral otalgia in 10 (40%). History of recurrence of tonsillitis prior to development of PA was positive in 15 (60%) of the PA patients while 10 (40%) had PA without antecedent tonsillitis (Table 2).

Examination finding showed that all the patients had some degree of trismus at presentation with 16 (64%) had mild degree

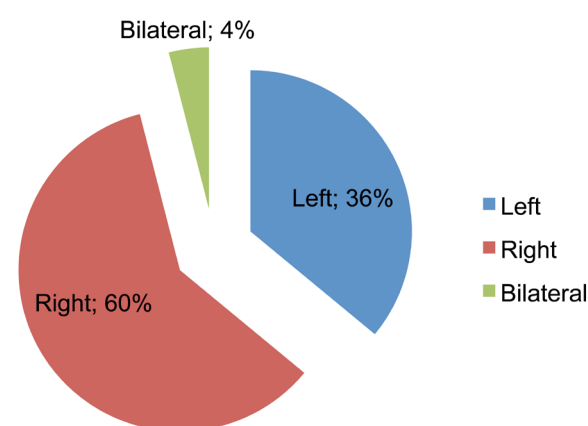


Figure 2: Site frequency chart or location of peritonsillar abscess at presentation.

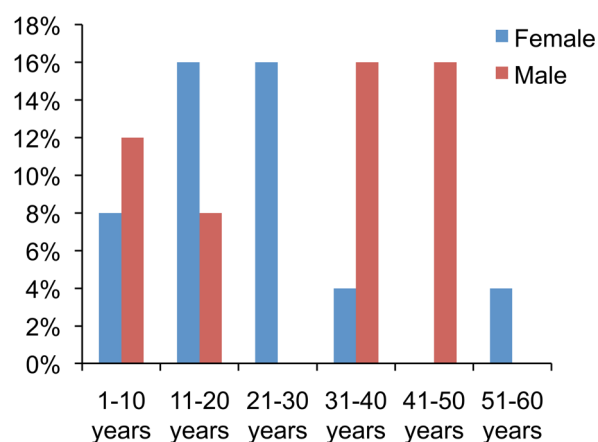


Figure 1: Age-sex frequency chart of patients with peritonsillar abscess.

Table 1: Cross tabulation of age (years) with duration of presentation (days)

Age (years)	Duration of Presentation (days)								Total
	4	5	6	7	8	9	11	12	
1–10 years	1	3	1	–	–	–	–	–	5
11–20 years	–	–	4	1	–	–	–	–	6
21–30 years	1	1	–	1	1	–	–	–	4
31–40 years	1	–	–	–	1	1	1	–	4
41–50 years	1	–	1	–	1	1	1	–	5
51–60 years	–	1	–	–	–	–	–	–	1
Total	5	5	6	2	3	2	2	–	25

Table 2: The clinical characteristics of peritonsillar abscess (PA), n = 25

Clinical Characteristics	Frequency (%)
Symptoms	25 (100)
Sorethroat	21 (84)
Fever	25 (100)
Muffled speech	18 (72)
Dysphagia	10 (40)
Ipsilateral otalgia	10 (40)
Signs	
Trismus	25 (100)
Drooling	10 (40)
Cervical lymphadenopathies	25 (100)
Significant histories	
Recurrent tonsillitis	15 (60)
Previous PA	0 (0)
Diabetes Mellitus	4 (16)

of trismus while 9 (36%) had moderate degree of trismus with drooling of saliva in 10 (40%). Associated tonsillar enlargement in 13 (52%) of the PA, they all had enlarged tender ipsilateral cervical lymphadenopathies (Table 2).

The duration of hospital stay varied from between 1 to 8 days with a mean duration of 4.2 days; 3.32 days (SD 1.1). The long hospital stay was due to inability to offset the hospital bill in two of the patients and two came from a far distance and were delayed hoping for complete resolution of all symptoms as there was the possibility of non-presentation for follow up. All the patients had incision and drainage of PA with no recurrence of symptoms.

Discussion

PA is a collection of pus between the fibrous capsule of the tonsil, usually at the upper pole, and the superior constrictor muscles of the pharynx. It may occur at any age but the majority is in young adults between 20 and 50 years of age, which is surprising in view of the fact that the incidence of tonsillitis peaks in childhood, suggesting the aetiology must be more complex (8,9). Our study however revealed peak prevalence among those in the age group of 11–20 years which is at variance with study by Tal et al. in 2010 (10) but majority of our study group still falls within the age group 20–50 years. PA is found to occur almost in the same ratio among both sexes in our study which is similar to findings in most literature reviewed. The tonsils is a paired organ in the oropharynx thus PA can occur on any side of the tonsils, our study revealed that PA is more commoner on the right than the left side compared to other study that found it commoner on the left side (10). There was only one case of bilateral PA which was an uncommon phenomenon and rarely reported (Figure 2). Various world literature reviewed (9–11) describe patients with PA as appearing ill and present with fever similar to findings in our series where almost all the patients (84%) had fever at presentation. There was also malaise in all the patients despite the commencement of treatment in some, sorethroat, dysphagia, or otalgia were also part of the complaints similar to what was documented in the literature (9–11). The throat pain is markedly more severe on the affected side probably due to inflammation, swelling, pressure, and stretch effect on the nerves and is often referred to the ear on the same side (referred otalgia) which was documented only in 40% of the patients reviewed. None of the patients had an antecedent acute pharyngotonsillitis or developed PA post-

tonsillectomy. This observation may suggest a different or an additional etiology for developing a PA rather than being regarded as a complication of acute pharyngotonsillitis. Additional information regarding the linkage of PA and pharyngotonsillitis may be attributed to the unexpected discrepancy between the peak occurrence of PA and that of tonsillitis among children and young adults (10). Physical examination usually reveals trismus as documented in literature was found in all our patients but was in grades or degree and varied from mild to moderate grades, because of pain from inflammation and spasm of masticator muscles (12). None of our patients reviewed had severe trismus. Swallowing was also painful, resulting in pooling of saliva or drooling (10–12). Patients often speak in a muffled voice (also called “hot potato voice”) which was found in all the patients. The duration of symptoms from our review found an average of 6.5 days which is slightly longer than findings from other studies with shorter hospital stay in Tanzania (9,12,13) compared to ours with longer hospital stay due to inability to pay hospital bills and also at the discretion of the managing physician to allow the symptoms to improve based on the far distance where the patient came from. None of our patients based on our review had any recurrence on follow up Our series did not assess for other co-morbidities such as smoking, alcoholism except for common conditions such as diabetes mellitus which we found only in about 16% of the study group, this is one of the deficiency being a retrospective study. The diagnosis of this condition is usually clinical based on history, physical examination including examination of the oral cavity and oropharynx confirmation with presence of a bulge in the peritonsillar area. A test aspirate usually yield purulent material which is sent for microscopy culture and sensitivity (MCS), however in our study only 3 of the patient submitted their specimen for MCS this may be associated with poor compliance to instruction to submit specimen as most drainage is done following aspirate (13–15). It was also found that the results of cultures obtained from peritonsillar abscesses did not alter management (13–15). Patients most of the time have relieve of symptom after commencement of antibiotic therapy based on local guidelines, before the culture was available 24–48 hours after presentation (9,10). Most aspirate yielded anaerobes and gram-negative rods as seen in previous study (6). All the patient had immediate relief of pain and pressure symptom after aspiration and drainage of the abscess, which may be responsible for poor

compliance to instruction to submit specimen and also follow up. All the patient were treated with incision and drainage offered for 24 (96%) and only 1 (4%) had wide bore needle aspiration done. None of the patients had recurrence of symptom after treatments as they never represented with the same symptoms on follow up.

Conclusion

In conclusion PA is an ENT emergency that is still found among our patients commoner among the young adult and middle aged, males more than female and the modality of treatment in our setting is still incision and drainage in our environment and follow up was a challenge.

Acknowledgement

The authors are really very grateful to the management of the national ear care center as well as the head of department and staff of the Medical health record department for assisting in retrieving the case notes of the patients.

Conflict of Interest

None.

Funds

None.

Authors' Contributions

Conception and design, statistical expertise, analysis and interpretation of the data: AOA
 Drafting of the article: AA, LS, SR, ME
 Critical revision of the article for the important intellectual content: LAS, ABM
 Final approval of the article: AOA, LAS, ABM
 Provision of study materials or patient: AA, ME
 Collection and assembly of data: LS, SR

Correspondence

Dr Afolabi Olushola Abdulrahman
 MBBS (ABU, Zaria), FWACS (Otorhinolaryngology West Africa), FMCORL (Nigeria)
 Department of ENT
 University of Ilorin/University of Ilorin Teaching Hospital, PMB 1459
 Ilorin, Nigeria
 Tel: +234 80357 27069
 Fax: +234 80357 27069
 Email: droaafolabi@yahoo.com

Reference

1. Farmer SEJ, Khatwa MA, Zeitoun HMM, Peritonsillar abscess after tonsillectomy: a review of the literature. *Ann R Coll Surg Engl.* 2011;**93(5)**:353–357. doi: 10.1308/003588411X579793.
2. Macnamara M. Acute and chronic pharyngeal infection. In: Gleeson M, Browning GG, Burton MJ, Clarke R, Hibbert J, Jones NS, et al. *Scott-Brown's Otorhinolaryngology, Head and Neck Surgery.* 7th ed. London (LDN): Hodder Arnold; 2008. p. 1981–2024.
3. Steyer TE. Peritonsillar abscess: diagnosis and treatment [Published correction appears in *Am Fam Physician.* 2002;**66(1)**:30]. *Am Fam Physician.* 2002;**65(1)**:93–96.
4. Khayr W, Taepke J. Management of peritonsillar abscess: needle aspiration versus incision and drainage versus tonsillectomy. *Am J Ther.* 2005;**12(4)**:344–350.
5. Hanna BC, McMullan R, Gallagher G, Hedderwick S. The epidemiology of peritonsillar abscess disease in Northern Ireland. *J Infect.* 2006;**52(4)**:247–253. doi: 10.1016/j.jinf.2005.07.002.
6. Megalamani SB, Suria G, Manickam U, Balasubramanian D, Jothimahalingam S. Changing trends bacteriology of peritonsillar abscess. *J Laryngol Otol.* 2008;**122(9)**:928–930. doi: 10.1017/S0022215107001144.
7. Cabrera CE, Deutsch ES, Eppes S, Lawless S, Cook S, O'Reilly RC, et al. Increased incidence of head and neck abscesses in children. *Otolaryngol Head Neck Surg.* 2007;**136(2)**:176–181.
8. Powell J, Wilson, JA. An evidence-based review of peritonsillar abscess. *Clin Otolaryngol.* 2012;**37(2)**:136–145. doi: 10.1111/j.1749-4486.2012.02452.x.
9. Nicholas JG. Peritonsillar abscess. *Am Fam Physician.* 2008;**77(2)**:199–202.
10. Marom T, Cinamon U, Itskoviz D, Roth Y. Changing trends of peritonsillar abscess. *Am J Otolaryngol.* 2010;**31(3)**:162–167. doi: 10.1016/j.amjoto.2008.12.003.
11. Nwe TT, Singh B. Management of pain in peritonsillar abscess. *J Laryngol Otol.* 2000;**114(10)**:765–767.
12. Wang X, Moshi NH. Management of peritonsillar abscess. *E Centr Afr J Surg.* 2000;**5(2)**:15–16.
13. Mehanna HM, Al-Bahnasawi L, White A. National audit of the management of peritonsillar Abscess. *Postgrad Med J.* 2002;**78**:545–548.
14. Cherukuri S, Benninger MS. Use of bacteriologic studies in the outpatient management of peritonsillar abscess. *Laryngoscope.* 2002;**112(1)**:18–20.
15. Repanos C, Mukherjee P, Alwahab Y. Role of microbiological studies in management of peritonsillar abscess. *J Laryngol Otol.* 2009;**123(8)**:877–879. doi: 10.1017/S0022215108004106.