

Abstract

After arising from the brachial artery in the cubital fossa the ulnar artery usually passes deep into the superficial flexor muscles of the forearm. In the lower two-thirds, it typically follows a sub-fascial course. In the present case, during a routine undergraduate course dissection of a cadaver, it was found that the ulnar artery arose normally as a terminal branch of the brachial artery in the cubital fossa, followed a sub-fascial course by lying superficial to the flexor muscles then completed the superficial palmar arch in hand. This artery gave only minute muscular branches in the forearm. Moreover, the main branches that usually arise from the ulnar artery were given off by the radial artery. This type of variation is of importance for both the clinicians and surgeons due to its vulnerability to injuries and of academic interest for anatomists.

Keywords: *brachial artery, common interosseous artery, radial artery, superficial palmar arch, superficial ulnar artery*

Introduction

The brachial artery usually terminates into two branches, the radial and ulnar arteries, in the cubital fossa. The ulnar artery is the principal source of blood supply to the forearm; while the radial artery typically supplies the hand (1). Anatomically the ulnar artery passes inferomedially deep to the median nerve and the muscles arising from both the medial epicondyle of the humerus and the coronoid process of the ulna. It accompanies the ulnar nerve and pierces the deep fascia just proximal to the flexor retinaculum. Within the cubital fossa, both the radial and ulnar arteries send recurrent branches that anastomose with those of the brachial and profunda brachii arteries. The common interosseous artery is the principal branch of the ulnar artery in the forearm. It passes to the upper border of interosseous membrane and divides into the anterior and posterior interosseous arteries (1). Interestingly, a "superficial" ulnar artery has been found that has an unusual course that originates from either the brachial or axillary artery. The prevalence of such variation has been shown in 0.7–9.4% of the population (2).

Case Report

During the routine dissection of a 50-year-old male cadaver in an undergraduate course, the students observed a unilateral variation of the

arterial pattern in the right forearm.

The ulnar artery originated as a terminal branch of the brachial artery in the cubital fossa as usual. However, it differed in its course through the forearm. The artery passed superficial to all of the superficial flexor muscles, which originate from the front of the medial epicondyle of the humerus. As it descended into the middle of the forearm, it followed the lateral border of the flexor carpi ulnaris muscle and then proceeded on a normal course. It passed superficial to the flexor retinaculum and then, divided into a superficial and deep branch. The superficial branch joined with the superficial palmar branch of the radial artery to complete the superficial palmar arch in the hand, whereas the deep branch joined the deep palmar arch. However, in the forearm, the ulnar artery produced only minute muscular branches to the superficial flexors of the forearm. The other branches (common interosseous, anterior ulnar recurrent and posterior ulnar recurrent), which are normally project from the ulnar artery, were unusually absent (Figure 1).

The radial artery, which is the other terminal branch of brachial artery, was radiated from the cubital fossa as usual, followed the normal course in the forearm. The radial artery also typically gives radial recurrent artery and a few muscular branches in the upper part of forearm. However, in the present case, the radial artery gave a medial common branch and a lateral common branch one inch below its origin. The medial common branch

divided into common interosseous and common recurrent arteries; the common recurrent artery further divided into the anterior and posterior ulnar recurrent arteries. Meanwhile, the lateral common branch further divided into the radial recurrent artery and a muscular branch (Figure

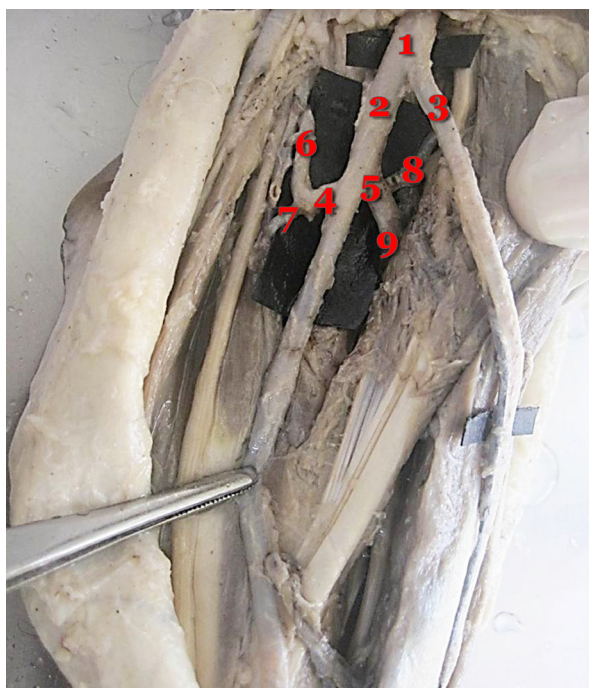


Figure 1: Anterior view of right forearm showing; 1-Brachial artery, 2-Radial artery, 3-Superficial ulnar artery, 4-Lateral common branch, 5-Medial common branch, 6-Radial recurrent artery, 7-Muscular artery, 8-Common recurrent artery, 9-Common interosseous artery.

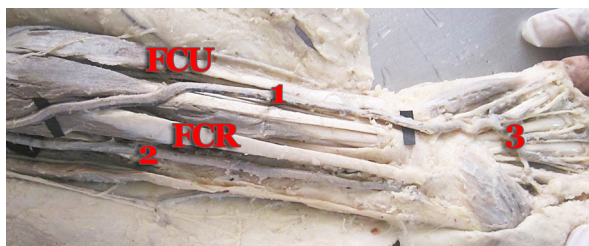


Figure 2: Anterior view of right forearm showing FCU-Flexor carpi ulnaris, FCR-Flexor carpi radialis, 1-Superficial ulnar artery, 2-Radial artery, 3-Superficial palmar arch. Note the absence of palmaris longus muscle.

1). Moreover, the palmaris longus muscle was absent. (Figure 2).

Discussion

Variations in the arterial pattern of the upper limb have already been reported in the literature (3). A high origin of the ulnar artery from the axillary artery, brachial artery, or superficial brachial artery is termed as the “superficial ulnar artery”. When produced by the brachial artery, this variation has been shown to arise very frequently from the lower third of the brachial artery, frequently from the upper third, and rarely from the middle third (3). It passes superficial to the superficial flexors of the forearm (4). Moreover the prevalence of the superficial ulnar artery is reported to be 0.7–9.4% in the population (2). In the present case, the artery was found to have the usual origin from the brachial artery within the cubital fossa. A superficial ulnar artery, that originates from the brachial artery in the arm, typically lays superficial (5) or deep (6,7) to the ante brachial fascia in the forearm. In the present case, no such finding was observed, since the ulnar artery branched out normally from the brachial artery in the cubital fossa. The ulnar artery also typically arises from the brachial artery and passes superficial to the flexor muscles of the forearm, giving off no important branch (8), as was the case in the current findings.

The radial artery, while in the cubital fossa, gives off a large branch, from which the anterior and posterior ulnar recurrent, radial recurrent, arteria nervi mediana, and the anterior and posterior interosseous, have their origins, all of which have a normal distribution (8). However, the present case was slightly different from this finding. Here, the radial artery actually gave off two large branches, a medial common branch (MCB) and a lateral common branch (LCB).

Embryological significance

The blood supply to the upper limb bud is furnished by the branches of the dorsal intersegmental arteries, which arise from the aorta and form a fine capillary network throughout the mesenchyme. This primordial vascular pattern consists of a primary axial artery and its branches that changes as the limbs develop, chiefly by new vessels being produced from existing vessels. These new vessels subsequently coalesce with additional sprouts to form new vessels. For instance, the primary axial artery becomes both the brachial artery in the arm and the common

interosseous artery in the forearm, which in turn has anterior and posterior interosseous branches. The ulnar and radial are the terminal branches of the brachial artery (9). As the limb bud grows, the common interosseous artery becomes incorporated into the ulnar artery. The developmental reason for the superficial ulnar artery in this case may be due to the radial artery establishing a connection with the axis artery of the forearm, thus giving rise to the medial common branch that branched further to give rise to the common interosseous and the common recurrent arteries.

Clinical significance

Since the artery in the present case was closely related to the median cubital vein, there is a high possibility of unintentionally penetrating the artery during attempts of venipuncture of the median cubital vein. Although the accidental intra-arterial injection of drugs is rare, if it occurs, amputation of the forearm or fingers is sometimes necessary (10).

The observed variation in the arterial pattern of the forearm also increases the possibility of inadvertent injuries occurring during surgery. As such one should always keep in mind the possible vascular variations before performing a surgery. Radiological examinations would help rule out any possible doubt about the variation at the site of surgery and hence prevent inadvertent injury to the ulnar artery. Taken altogether, although unlikely, variations in the ulnar artery demand a more detailed description owing to its surgical importance.

Acknowledgment

The authors are grateful to the non-teaching staff for their technical support.

Conflict of Interest

None.

Funds

None.

Authors' Contributions

Conception and design: LSQ
Analysis and interpretation of the data, drafting of the article: LSQ, NB

Critical revision of the article for the important intellectual content, provision of study materials or patient: ASD

Final approval of the article: LSQ, NB, ASD

Correspondence

Ms Lydia Shobha Quadros
MSc Medical Anatomy (Manipal University)
Department of Anatomy
Kasturba Medical College, Manipal University
Madhav Nagar, Manipal
Karnataka, 576104 India
Tel: +08202922327
Email: lidibudy@gmail.com

References

1. Romanes GJ. *Cunningham's manual of practical anatomy*. 15th ed. New York (NY): Oxford University Press; 1986. p. 82–83.
2. Sieg P, Jacobsen HC, Hakim SG, Hermes D. Superficial ulnar artery: curse or blessing in harvesting fasciocutaneous forearm flaps. *Head Neck*. 2006;**28**(5):447–452. doi: 10.1002/hed.20367.
3. Bergman RA, Thompson SA, Afifi AK, Saadeh FA. *Compendium of human anatomic Variations: Catalogue, atlas and world literature*. Baltimore/ Munich (BWI/MUC): Urban and Schwarzenberg; 1988.
4. Rodriguez-Niedenfuhr M, Vazquez T, Nearn L, Ferreira B, Parkin I, Sanudo JR. Variations of the arterial pattern in the upper limb revisited: morphological and statistical study, with a review of the literature. *J Anat*. 2001;**199**:547–566. doi: 10.1046/j.1469-7580.2001.19950547.
5. Reddy S, Vollala VR. Superficial ulnar artery-Development and clinical significance. *J Vasc Bras*. 2007;**6**(3):285–288. doi: 10.1590/S1677-54492007000300013.
6. Rodriguez-Baeza A, Nebot J, Ferreira B, Reina F, Perez J, Sanudo JR, et al. An anatomical study and ontogenic explanation of 23 cases with variations in the main pattern of the human brachio-antebrachial arteries. *J Anat*. 1995;**187**(2):473–479.
7. Bhat KMR, Potu BK, Gowda S. High origin of ulnar artery in South Indian male cadaver: a case report. *Rom J Morphol Embryol*. 2008;**49**(4):573–575.
8. Heuston FT. Notes on some anatomical anomalies. *Royal academy of medicine in Ireland*. 1885;**3**:453–456.
9. Moore KL, Persaud TVN. *The developing human - Clinically oriented embryology*. 7th ed. Philadelphia (PA): Pennsylvania. 2005. p. 412–414.
10. Chin KJ, Singh K. The superficial ulnar artery-a potential hazard in patients with difficult venous access. *Br J Anaesth*. 2005;**94**(5):692–693.