

# The Importance of Early Recognition of Cerebral Venous Sinus Thrombosis: A Case Report

Kian Guan Goh<sup>1</sup>, Viswanathan SHANTHI<sup>2</sup>

Submitted: 8 Sep 2014

Accepted: 2 Dec 2014

<sup>1</sup> Faculty of Medicine, University Malaya Medical Centre, Lembah Pantai, 59100 Kuala Lumpur, Malaysia

<sup>2</sup> Department of Neurology, Hospital Kuala Lumpur, Jalan Pahang, 50586 Kuala Lumpur, Malaysia

## Abstract

A 33-year-old lady presented to the emergency department (ED) of Kuala Lumpur Hospital with subacute onset of headaches, irritability, and vomiting. Neurological examination revealed a restless agitated patient, poor responses to verbal commands with a Glasgow Coma Scale of 14/15, photophobia, blurred nasal margins with generalised weakness, hyperreflexia, and downgoing plantars. Computed tomography (CT) of the brain showed evidence of biparietal infarction with an empty delta sign. Urgent magnetic resonance imaging and venography (MRI/MRV) of the brain in the ED showed evidence of thrombosis of the superior sagittal sinus extending to the torcular herophili, straight sinus, transverse sinuses, sigmoid sinuses, and proximal internal jugular veins. The precipitating factor for the thrombosis was possibly oral contraceptive pill usage, which she had been taking for a month. She was treated aggressively with anticoagulation. The patient subsequently improved symptomatically and achieved full neurological recovery. In this patient, early recognition of the clinical symptoms and a CT scan with confirmation by MRI/MRV of the brain enabled the prompt diagnosis and treatment of cerebral venous sinus thrombosis with a good clinical outcome.

**Keywords:** cerebral venous thrombosis, computed tomography, magnetic resonance imaging, oral contraceptive, anticoagulation

## Introduction

Cerebral venous sinus thrombosis (CVST) is a rare disease that has a wide range of presentations, from headache to focal neurological deficits. There is an urgent need for accurate diagnosis and early treatment to reduce morbidity and mortality. The causes of CVST range from prothrombotic disorders (such as malignancies, haematological disorders and vasculitis) to pregnancy, puerperium, and drugs.

This case report describes a patient who recently started oral contraceptive pills and subsequently developed subacute headaches with altered behaviour. She was promptly diagnosed as CVST based on computed tomography (CT) imaging of the brain, which was further confirmed with magnetic resonance imaging and venography (MRI/MRV) scans of the brain. She made a complete neurological recovery after starting anticoagulation.

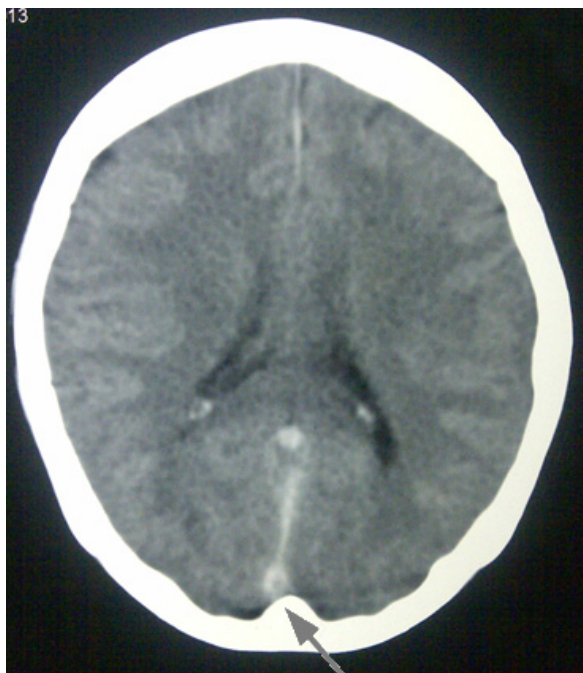
## Case Report

A 33-year-old married Burmese lady presented with subacute onset of severe frontal headaches of one week duration worsening over one day. The headaches were unresponsive to conventional analgesics. This was followed by behavioural changes consisting of irritability and agitation with mild confusion and photophobia. It was also associated with general malaise, nausea and difficulty in weight bearing for two days prior to admission. She denied having visual loss or seizures. Systemic complaints and constitutional symptoms suggestive of chronic infection or malignancies, such as cough, fever, loss of weight, chronic diarrhoea, reduced effort tolerance or bleeding per vagina, were absent. She also denied pregnancy symptoms and had just switched to oral contraceptives, which she had been taking for one month. Neurological examination revealed a restless, agitated photophobic patient without

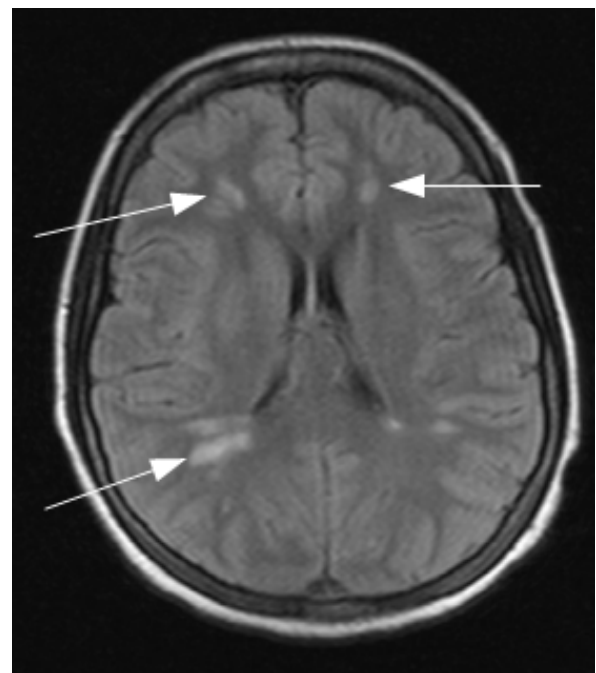
neck stiffness but with a Glasgow Coma Scale of 14/15, mild nasal blurring of the fundic margins and pyramidal weakness more over the right than left side with power of 2/5 compared to 3/5. Her reflexes were brisk and plantars were down going bilaterally. A CT scan of the brain done in the emergency department showed an area of subcortical white matter low-density changes in both parietal lobes, which indicated bilateral high parietal infarction. There was a low-density filling defect in the posterior part of the sagittal sinus, also known as an empty delta sign. MRI/MRV of the brain showed thrombosis of the superior sagittal sinus extending to the torcular herophili, straight sinus, transverse sinuses, sigmoid sinuses and proximal internal jugular veins. There were also multifocal acute infarctions in the bilateral fronto-parieto-occipital white matter. Blood test results showed haemoglobin of

10.6 g/dL, a total white cell count of 13 000 and a platelets count of 365 000. The renal and liver tests were within normal limits. Thrombophilia screening, including an antiphospholipid screen, was done and was within normal limits. Anticardiolipin antibody, lupus anticoagulant, and anti- $\beta$ 2-glycoprotein were negative. A lumbar puncture showed normal pressure with normal biochemistry and an absence of pleocytosis. Low molecular weight heparin was started and subsequently the patient was anticoagulated with warfarin for a total period of three months.

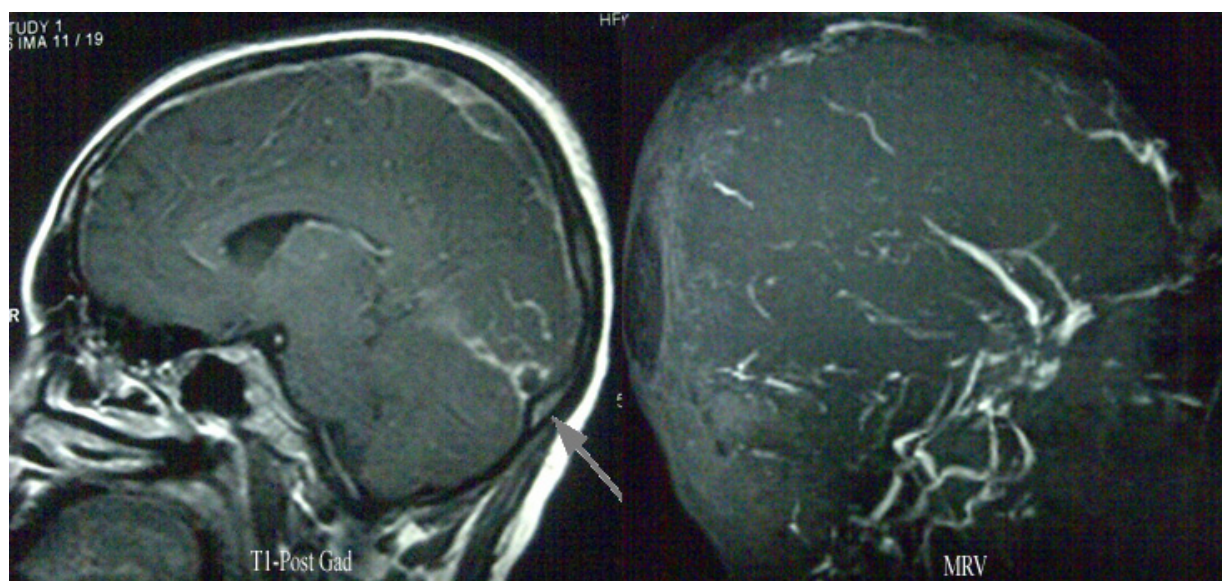
She progressed well in the ward with a full neurological recovery within 48 hours of admission. She was ambulating in the ward by day three and had no further behavioural issues, seizures or headaches. She was referred to the gynaecological team and her oral contraceptive was stopped in favour of barrier contraception.



**Figure 1:** CT imaging of the brain showed a low-density filling defect in the posterior part of the sagittal sinus which signified an empty delta sign (arrows).



**Figure 2:** Multifocal signal hyperintensity changes in the subcortical white matter of the bilateral fronto-parietooccipital regions (white arrows) using a fluid-attenuated inversion recovery (FLAIR) sequence.



**Figure 3:** T1-weighted post-gadolinium MRI of the brain showing a filling defect in the transverse sinus and superior sagittal sinus (arrow) with MRV revealing thrombosis in the same area.

## Discussion

Cerebral venous and sinus thrombosis is a rare cause of stroke and occurs in five people per million (1). The diagnosis of CVST is often obscured because of the wide variety of symptoms which range from altered sensorium, focal neurological signs and seizures to symptoms of raised intracranial pressure, such as vomiting and blurring of vision. Other rare symptoms like thunderclap headaches that mimic subarachnoid haemorrhage have been reported in three case reports (2).

The causes of CVST are similar to those of venous thrombosis, such as deep vein thrombosis and pulmonary embolism. Often, there is more than one risk factor coexisting in the patient. In this case, the obvious risk factor was the recent introduction of oral contraceptive pills (OCP). It is the most frequent cause of CVST in women, accounting for up to 47% of diagnoses. The risk of thrombosis is increased further when patients who take OCP have congenital thrombophilia, such as the factor V Leiden mutation (3). Third-generation OCPs are associated with a greater risk of CVST compared to other OCPs (4).

With advances in neuroimaging technology, the diagnosis of CVST has become more common. However, CT scans of the brain still remain the initial workout for CVST. This is to eliminate causes that might mimic CVST. Roland et al. demonstrated a sensitivity of 73% in diagnosing

CVST using unenhanced CT brain scans. The signs to look for in a CT scan are the string signs, deep triangle signs as well as empty delta signs (5). However, up to 30% of initial CT scans are normal. Alternatively, a CT venogram of the brain has better sensitivity for picking up CVST and has the advantages of being a quicker scan, better tolerated by the patient and more widely available (6). There is a role for early MRI and MRV of the brain as a confirmatory test. They have greater sensitivity compared to CT imaging. The sequence used is T1 weighted, T2 weighted, fluid-attenuated inversion recovery (FLAIR), diffusion-weighted and venography. Venous infarction, haemorrhage, parenchymal changes, and the presence of thrombus are among the features present in the MR imaging of people with CVST (6).

In our case it is important to highlight that early recognition of cerebral venous thrombosis with high parietal lobe infarction which is not typical in its distribution for an arterial stroke and the presence of an empty delta sign on the plain CT scan which enabled the timely confirmation of the diagnosis by MRI/MRV with a good patient outcome.

The mainstay of treatment for CVST during the acute phase is anti-coagulation with either low-molecular weight heparin or unfractionated heparin is once a diagnosis of CVST has been confirmed. This is followed by vitamin K antagonists (VKA) if there are no

contraindications. The duration of the VKA treatment depends on the underlying cause. If the cause of CVST is transient, such as pregnancy, puerperium or drug-induced, then the treatment with VKA will be between three to six months. If there is mild thrombophilia, the duration of the VKA treatment will be between six to 12 months; however, if severe thrombophilia is present, then indefinite VKA treatment may be considered.

During acute treatment, seizure is treated with antiepileptics but there is no clear evidence for prolonged antiepileptic treatment. There is also no evidence to support the use of intravenous thrombolysis. A case report of mechanical thrombectomy using the Penumbra® system was able to demonstrate good neurological recovery in the patient. Generally, these procedures are reserved for patients that symptomatically worsen despite the best medical treatment (7).

In patients with papilloedema that threatens their vision, lumbar puncture is done to reduce intracranial pressure (ICP) before initiating heparin. Alternatively, acetazolamide and surgical procedures, such as lumboperitoneal shunts, ventriculoperitoneal shunts, and optic nerve fenestration, can be used. For cases with severely raised ICP, osmotic therapy with glycerol or mannitol is helpful. These patients usually need to be monitored, especially the ICP, in the intensive care unit settings. Hyperventilation can reduce ICP. Patients with impending herniation of the brain can benefit from a decompressive hemicraniectomy (1).

According to the International Study on Cerebral Vein and Dural Sinus Thrombosis, despite early diagnosis and treatment, the mortality of CVST during the acute phase is 5.6% (1). As this disease predominantly affects people in the young and productive age groups, it can lead to loss of productivity. In our patient, despite the absence of infection or prior thrombotic risk factors, the commencement of OCP for contraceptive purposes over a period of a month was enough to trigger an episode of CVST. S. Jick and H. Jick showed that the highest risk of developing CVST in women taking different types of OCP is 2.7 per 100 000 woman-years (8). This leaves room for further research on pharmacogenetics to provide information on the safety of initiating OCP.

In conclusion, early recognition derived from the patient's history at emergency department-level and knowledge of CT brain changes in CVST enabled a prompt diagnosis by MRV and the initiation of treatment with a good clinical outcome in our case study.

## Acknowledgement

None.

## Conflict of interest

None.

## Funds

None.

## Authors' Contributions

Drafting of the article: GKG

Final approval of the article: SVS

## Correspondence

Dr Kian Guan Goh  
MD (Universiti Kebangsaan Malaysia)  
No 1, Lorong Galing 112  
Taman Imbi, Air Putih  
25300 Kuantan  
Pahang, Malaysia  
Tel: +603-7949 2585  
Fax: +603-7949 4613  
Email: egangoh@gmail.com

## References

1. Bousser M-G, Ferro JM. Cerebral venous thrombosis: an update. *Lancet Neurol*. 2007;**6(2)**:162–170. doi: 10.1016/S1474-4422(07)70029-7.
2. Brujin SFTM De, Stam J, J KL. Early reports Thunderclap headache as first symptom of cerebral venous sinus thrombosis. *Lancet*. 1996;**348(9042)**:1623–1625. doi: 10.1016/S0140-6736(96)07294-7.
3. Bousser M-G, Crassard I. Cerebral venous thrombosis, pregnancy and oral contraceptives. *Thromb Res*. 2012;**130 (1 Suppl)**:S19–S22. doi:10.1016/j.thromres.2012.08.264.
4. Brujin SFTM de, Stam J, Vandenbroucke JP. Increased risk of cerebral venous sinus thrombosis with third- generation oral contraceptives. *Lancet*. 1998;**351(9113)**:1404.
5. Guenther G, Arauz a. Cerebral venous thrombosis: A diagnostic and treatment update. *Neurologia*. 2011;**26(8)**:488–498. doi: 10.1016/j.nrleng.2010.09.002.

6. Connor SEJ, Jarosz JM. Magnetic resonance imaging of cerebral venous sinus thrombosis. *Clin Radiol*. 2002;**57(6)**:449–461. doi: 10.1053/crad.2001.0880.
7. Velat GJ, Skowlund CJ, Waters MF, Mocco J, Hoh BL. Direct thrombectomy using the Penumbra thromboaspiration catheter for the treatment of cerebral venous sinus thrombosis. *World Neurosurg*. 2012;**77(3-4)**:591.e15–8. doi: 10.1016/j.wneu.2011.02.020.
8. Jick SS, Jick H. Cerebral venous sinus thrombosis in users of four hormonal contraceptives: levonorgestrel-containing oral contraceptives, norgestimate-containing oral contraceptives, desogestrel-containing oral contraceptives and the contraceptive patch. *Contraception*. 2006;**74(4)**:290–292. doi: 10.1016/j.contraception.2006.05.071.