

# Traumatic Pseudoaneurysm of Right Extracranial Internal Carotid Artery: A Rare Entity and Recent Advancement of Treatment with Minimally Invasive Technique

Joo Lian Julian ONG<sup>1</sup>, Salmah JALALUDIN<sup>2</sup>

Submitted: 23 Sep 2014

Accepted: 17 Dec 2014

<sup>1</sup> Department of Radiology, Sarawak General Hospital, Jalan Hospital, 93586 Kuching, Sarawak, Malaysia

<sup>2</sup> Department of Radiology, School of Medical Sciences, Universiti Sains Malaysia, 16150 Kubang Kerian, Kelantan, Malaysia

## Abstract

The purpose is to describe a case of traumatic right extracranial internal carotid artery (EICA) pseudoaneurysm, which is a rare entity and the evolution of treatment from surgery to minimally invasive intervention by endovascular stenting and coiling. We reported a case of traumatic right EICA pseudoaneurysm who presented with multiple cranial nerve palsies. Multiple radiological examinations [including magnetic resonance imaging (MRI) with angiogram, computed tomography angiogram (CTA), and digital subtraction angiogram (DSA)] demonstrated right EICA pseudoaneurysm. The pseudoaneurysm was successfully treated with endovascular stenting and coiling. EICA pseudoaneurysm is a rare entity, and open surgery was the gold standard of treatment. Current technology allows endovascular stenting and coiling of pseudoaneurysm as an alternative treatment. It is minimally invasive, associated with lesser complications, better recovery and a shorter hospital stay.

**Keywords:** carotid artery, internal, pseudoaneurysm, digital subtraction angiography, computed tomography

## Introduction

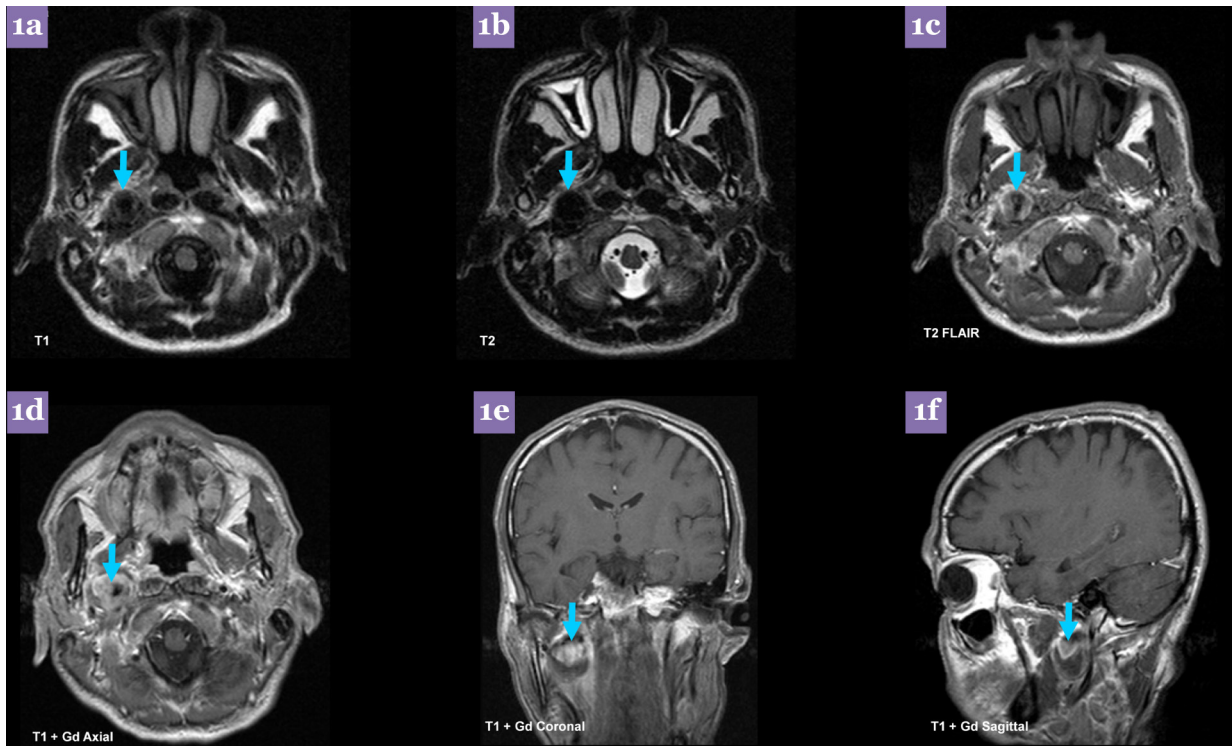
Extracranial internal carotid artery (EICA) traumatic pseudoaneurysm is a rare entity, and they are prone to thromboembolic event. Other associated complications include cranial nerves palsies, ruptures and haemorrhages. Medical treatment with anticoagulants and antiplatelets alone is ineffective with high morbidity and mortality. Total resection of pseudoaneurysm with end-to-end anastomosis or interposition of gap by synthetic or saphenous vein grafts is the gold standard of treatment. However, it is associated with significant morbidity and mortality. Endovascular stenting with or without coiling is a minimally invasive technique and emerging alternative to surgical treatment. Nitinol self-expandable stent is a preferable choice than balloon expandable stent for treating EICA aneurysm due to its advantages of being more physiological, superelastic for withstanding extrinsic pressure, better wall apposition, flow diverting effect and better radio-opaque markers.

## Case report

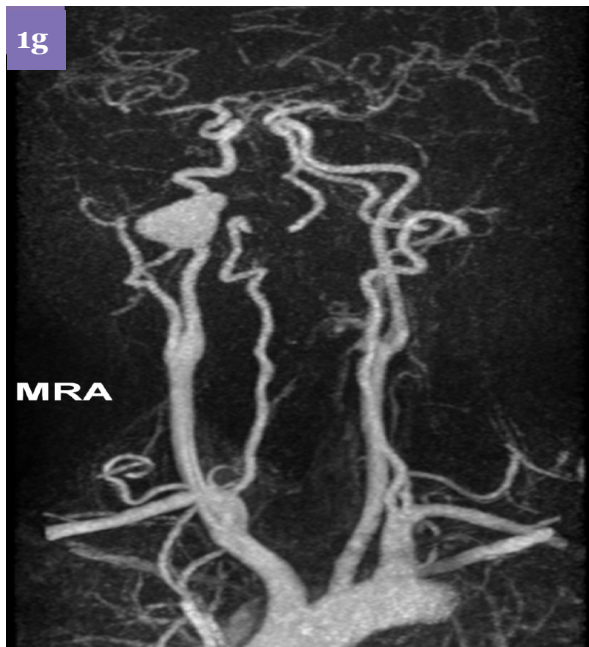A 40-year-old man who was involved in a motor vehicle accident two months ago developed hoarseness of voice with cranial nerves IX, X, XI & XII palsies. Laryngoscope performed revealed right vocal cord palsy in abduction, with no compensation of left vocal cord.

Magnetic resonance imaging (MRI) of the brain was done and showed no intracranial pathology. MRI of the neck with angiography demonstrated a 2.5 cm pseudoaneurysm with heterogeneously hyper-intense signal on both T1 and T2 weighted images and heterogeneously enhancing post contrast at right parapharyngeal space. (Figure 1a-1f) The pseudoaneurysm arises from the cervical portion of the right internal carotid artery (ICA). The right ICA was patent (Figure 1g).

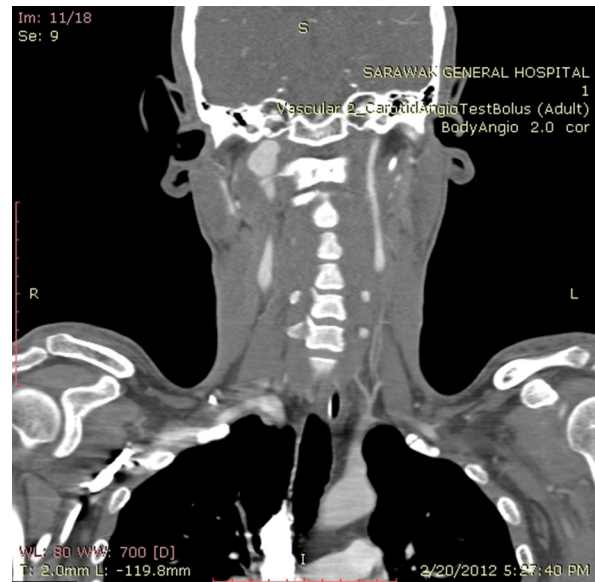
Computed tomography angiogram (CTA) demonstrated a pseudoaneurysm of the cervical portion of the right ICA at C1/C2 level (Figure 2). The pseudoaneurysm was well opacified with contrast material, and the ICA superior and



**Figure 1 (a–f):** MRI at the upper cervical region demonstrating a heterogeneously hyperintense pseudoaneurysm with heterogenous enhancement at right parapharyngeal space.



**Figure 1g:** Magnetic resonance angiography demonstrates a pseudoaneurysm involving the cervical portion of right ICA.



**Figure 2:** CTA demonstrates right extracranial ICA pseudoaneurysm at C1/C2 level.

inferior to the pseudoaneurysm was patent. The left internal carotid artery, basilar artery, bilateral common carotid, external carotid and vertebral arteries were intact. CT of the neck revealed that the right vocal cord was abducted, while the left vocal cord was in normal position.

Digital subtraction angiography (DSA) was performed. It demonstrated a saccular pseudoaneurysm at cervical portion of the right ICA, arising 5 cm from the carotid bifurcation. The pseudoaneurysm measures 1.7 cm × 2.5 cm (Figure 3a). Two LEO + (Balt Extrusion, Montmorency, France) nitinol flexible self expanding stents were deployed across the neck of the pseudoaneurysm, and it was lightly packed with coils to induce thrombosis. Post-stenting angiogram showed good patency of the right ICA with improved flow intracranially. Partial thrombosis of the pseudoaneurysm was evidenced. (Figure 3b).

Post-stenting and embolisation, patient was started with amlodipine 10 mg/day and aspirin 150 mg/day. One year after the stenting and embolisation, repeat DSA showed minimal residual aneurysm. (Figure 3c). There was no deterioration of his clinical symptoms. Aspirin was discontinued with continuation of amlodipine. His blood pressure was within the normal limit.

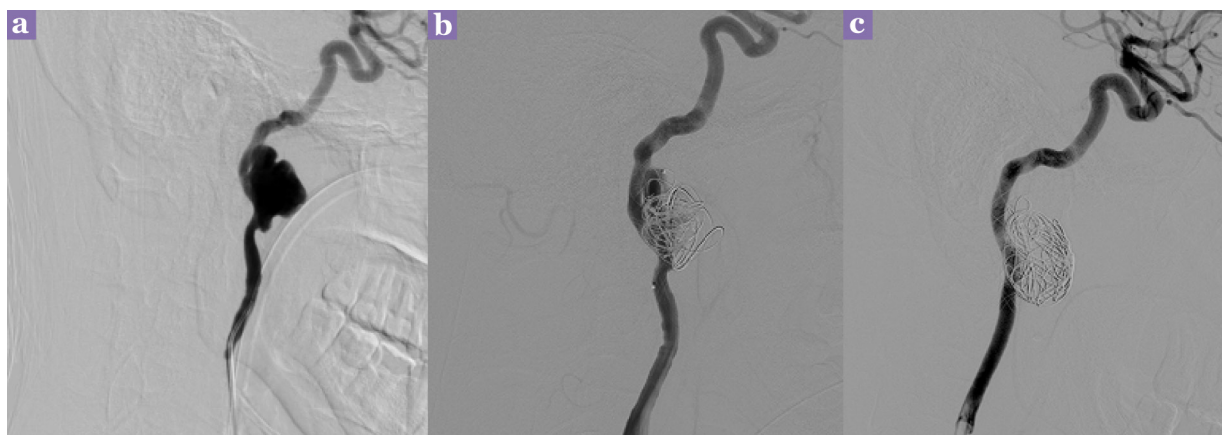## Discussion

Extracranial internal carotid artery (EICA) aneurysm is a rare entity, accounting for 0.8% to 1% of all arterial aneurysms (1). They are defined as more than 50% focal dilatation of the ICA diameter as compared with the reference

values ( $0.55 \pm 0.06$  cm in men;  $0.49 \pm 0.07$  in women) (2). There are two types of aneurysms, namely true aneurysms or pseudoaneurysms. Pseudoaneurysms of the internal carotid artery are less common than true aneurysms comprising 14% of cases. True aneurysms are most commonly due to atherosclerosis or fibromuscular dysplasia. The major cause of pseudoaneurysm is previous endarterectomy. Other causes include trauma and infections. Traumatic pseudoaneurysm is most commonly due to motor vehicle accident (69%), followed by stab-wounds, iatrogenic central venous cannulation, sport accident, a fight, a fall or cervical manipulation. The incidence of EICA injury in patients with blunt trauma is about 0.08%. Infection was the main cause of EICA aneurysms before the antibiotic era.

Traumatic pseudoaneurysms of EICA are either caused by compression and stretching of the artery on the lateral mass of the atlas or shearing of the artery before entering carotid canal (3). The diagnosis is often delayed due to other associated injury and delayed manifestation of the clinical signs (3). EICA pseudoaneurysms may be asymptomatic, accounting of 30% – 60% of cases. EICA pseudoaneurysms can be partially or completely thrombosed and may lead to embolisation with cerebral infarction. The enlarging pseudoaneurysm may present as a pulsating neck mass with mass effect and resulting cranial nerve palsies. Other complications include ruptures with haemorrhage (1).

Conservative treatment with anticoagulants and antiplatelets can be considered for a young patient without symptoms (4). However, in many



**Figure 3:** (a) Lateral view of DSA demonstrated right cervical portion ICA pseudoaneurysm with wide neck; (b) Post-stenting and coiling angiogram showed good patency of the right ICA with improved flow intracranially. Partial thrombosis of the pseudoaneurysm was evidence; and (c) Repeat DSA one year post-stenting and embolization revealed minimal residual aneurysm.

cases, medical treatment is ineffective as 40% of them do not heal (5). It can even be dangerous with the added risk of haemorrhage. The overall estimated complication rate ranges from 20%–71% with medical treatment.

Therefore, surgery is recommended particularly for symptomatic pseudoaneurysms in patients of all ages. Total aneurysmectomy with end-to-end anastomosis is the surgery of choice. Alternatively, the gap can be interposed with a synthetic graft or a saphenous vein graft. For patients who underwent surgery, the mortality rate is 10% and the incidence of severe stroke is 3%, which are both relatively high (3).

In recent years, minimally invasive treatment with endovascular stenting with or without coiling of the pseudoaneurysm has become more popular. The achievement of immediate revascularisation may eliminate anticoagulation therapy. Self-expanding stents are a better choice than balloon expandable stents in the internal carotid artery. The extrinsic pressure encounter at this region may cause permanent collapse of the stent. Nitinol stents, such as LEO +, are superelastic and effective in counteracting on the extrinsic pressure. They exert a gentle chronic outward force and are more physiological. They are braided stents which provide better wall apposition, owing to small pores with flow diverting effect and better radio-opaque markers.

### Acknowledgement

None.

### Conflict of Interests

None.

### Funds

None.

### Authors' Contributions

Conception and design, analysis and interpretation of the data, drafting of the article: JOJL

Critical revision of the article for important intellectual content and final approval of the article: SJ

### Correspondence

Dr Julian Ong Joo Lian  
MD (UNIMAS), MMed (USM, NUS), FRCR (UK)  
Department of Radiology  
Sarawak General Hospital  
Jalan Hospital  
93586 Kuching  
Sarawak, Malaysia  
Tel: 013-806 1008  
Fax: 082-276841  
Email: ong\_julian@yahoo.com

### References

1. Alpagut U, Ugurlucan M, Kafali E, Ali Sayin O, Demir T, Basaran M et al. Aneurysm of the kinked extracranial internal carotid artery case report and review of the literature. *Acta Chir Belg.* 2005; **105(4)**:407–409.
2. Biasi L, Azzarone M, De Troia A, Salcuni P, Tecchio T. Extracranial internal carotid artery aneurysms: case report of a saccular wide-necked aneurysm and review of the literature. *Acta Biomed.* 2008;**79(3)**: 217–222.
3. Alimi YS, Di Mauro P, Fiacre E, Magnan J, Juhan C. Blunt injury to the internal carotid artery at the base of the skull: six cases of venous graft restoration. *J Vasc Surg.* 1996;**24(2)**:249–257. doi: 10.1016/S0741-5214(96)70100-3.
4. El-Sabroun R, Cooley DA. Extracranial carotid artery aneurysms: Texas Heart Institute experience. *J Vasc Surg.* 2000;**31(4)**:702–712. doi: 10.1067/mva.2000.104101.
5. Or Cohen-Inbar, Yaaqov Amsalem, Jean F. Soustiel. Nitinol Stenting in Post-Traumatic Pseudo-Aneurysm of Internal Carotid Artery. *Open J Modern Neurosurgery.* 2012;**2**:45–49. doi: 10.4236/ojmn.2012.23009.