

Microaneurysms (MAs) Localization for Severity Assessment

Open
Access

Nuraina Nadiah Muhamad Junaidi¹, Haniza Yazid^{1,*}

¹ School of Mechatronic Engineering University Malaysia Perlis (UniMAP), Kampus Ulu Pauh 02600 Arau, Perlis, Malaysia

ARTICLE INFO

Article history:

Received 18 August 2017
Received in revised form 4 October 2017
Accepted 2 December 2017
Available online 18 December 2017

Keywords:

Diabetic retinopathy, Microaneurysms, classification

ABSTRACT

Diabetic Retinopathy (DR) is a retinal complication that can cause blindness in diabetic patients. The early signs of diabetic retinopathy can be identified by the presence of microaneurysms (MAs) in the retina of the patients. The number of the MAs can indicate the severity of the disease. In this paper, the detection of the MAs using image processing techniques are proposed in order to determine the severity of MAs by counting the number of MAs in the image. In this work, 30 images from MESSIDOR and ImageRet database were utilized and the average accuracy obtained is 99.7%.

Copyright © 2017 PENERBIT AKADEMIABARU - All rights reserved

1. Introduction

Diabetes mellitus is always known as diabetes, which can be characterized as a chronic increase of glucose in the blood and is a metabolic abnormality because there is a failure to utilize glucose and hence a state of hyperglycemia can occur. Diabetes has become one of the most rapidly increasing health and is a disease that is famous all over the world that may cause abnormalities in the kidneys, nerve and retina (diabetic retinopathy). Patients with diabetes may have blurred vision and flashes, and sudden loss of vision is the most common symptoms of Diabetic Retinopathy (DR). More than 75% of DR patient will have some form of DR, if they have had diabetes for more than 20 years [1-3].

There are two clinical types of DR, which is Proliferative diabetic retinopathy (PDR) and Non-proliferative diabetic retinopathy (NPDR). NPDR also known as background DR and is a common and it is the earliest stage of the DR formation. NPDR can cause changes in the eye, including microaneurysms (MAs), retinal hemorrhages, hard exudates, macular edema, and macular ischemia. There are four stages of the NPDR namely normal, mild, moderate and severe [4]. The major lesions of the early DR include exudates, microaneurysms (MAs), hemorrhages (H) and cotton wool [5]. Microaneurysms (MAs) occur due to dilation of the blood capillaries and circular in shape. MAs also appear as small dots within 10 to 100 microns diameter and red in color. Figure 1

* Corresponding author.

E-mail address: hanizayazid@unimap.edu.my (Haniza Yazid)

(a) and Figure 1(b) show the original image of the retinal for a normal person and a person affected by DR.

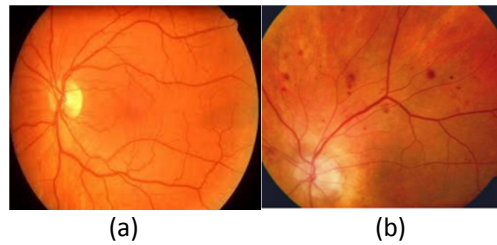


Fig. 1. (a) Retina of a normal person (b) Retina of a person affected by DR
The MAs location can be used for grading purposes. The retina image is divided into four quadrants. From that, by counting the number of MAs, the severity of the disease is identified and then the DR is graded.

2. Literature Review

Sujith Kumar *et al.* [7], proposed three stages to detect the DR. The first step is a preprocessing, feature extraction and the last stage is classifier. In addition, Akara Sopharak *et al.* [4], proposed three main stages. The first step is preprocessing step. Initially, the green channel image was extracted. Then, the noise was removed before using a Contrast Limited Adaptive Histogram Equalization (CLAHE). Afterwards the bright and dark region were detected using mathematical morphological methods. Finally, the closing operation is used to detect the MAs. Muhammad Faisal *et al.* [8] converted RGB image to grey scale to get the bright feature. They used adaptive histogram to increase the contrast of the image and use mathematical morphology such as opening and closing operations to eliminate the blood vessel in the image. For classification of the DR, they used Support Vector (SVM). SVM can classify the data into more than two classes. Shetty *et al.* [9], proposed a method for detecting the microaneurysms and grade the DR by removing background noise, normalization the intensity, removing reflections, and masking method. Then, they removed the blood vessel by using the Boolean valued feature and Circular Hough-Transformation is used to detect the MAs.

3. Proposed Approach

The proposed method for MAs detection consists of image acquisition, pre-processing, segmentation, detection and classification. The overall approach is denoted in Fig. 2.

3.1 Image Acquisition

This paper uses several images from the MESSIDOR and ImageRet database [10]. In MESSIDOR database, the image is acquired by using a color video 3CCD camera on a Topcon TRC NW6 non-mydratic camera with a 45 ° FOV. ImageRet database is provided for public in 2008 and it divides into two sub-database which include DIARETDB0 and DIARETDB1 [11]. For DIARETDB0, it contain 130 images which is 20 are normal and 110 contain various signs of diabetic retinopathy.

Meanwhile DIARETDB1 contains 89 images. 5 images represent healthy retinas while the other 84 contain diabetic retinopathy signs. The images were acquired with a 50 ° FOV. There are four experts that annotated the presence of hemorrhages, hard and soft exudates and microaneurysms.

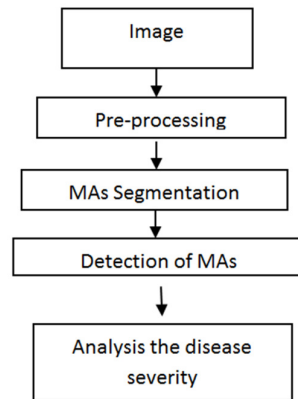


Fig. 2. Block diagram of the proposed MAs detection

3.2 Divide Image into Four Quadrants

First and foremost the image is divided into four quadrants as shown in Figure 3.

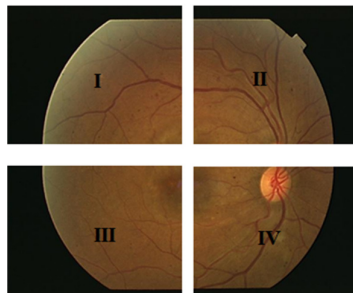


Fig.3. Four quadrants

3.3 Pre-processing

This method can help in simplifying the following steps such as segmentation, blood vessel detection and other abnormal structures. The main objectives of image pre-processing methods are to improve the contrast, attenuate image variation, and eliminate the noise and to correct the non-uniform illumination problem. One of the main purpose is to improve the contrast of the retinal image so that we can easily detect and localize optic disc, blood vessel and microaneurysms. The method involved in this stage is presented in the Figure 4.

3.3.1 Green channel

In pre-processing stage, the original image is converted into green channel. Its exhibits the best because it has a high intensity compared to the red and blue channel. Besides that, green channel image is used as it contains the maximum contrast [12].

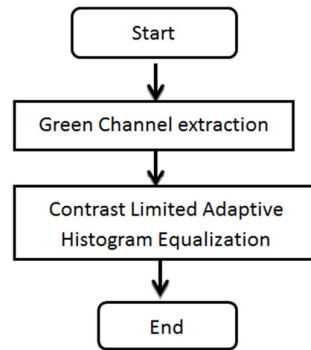


Fig. 4. Flowchart of the proposed pre-processing

3.3.2 Contrast enhancement

Contrast Limited Adaptive Histogram Equalization (CLAHE) was applied onto the green image. Contrast enhancement method was used to improve the visual appearance that makes an object distinguishable from other objects and the background.

3.4 Segmentation

Segmentation is a process of dividing images into subsections. In this work, several segmentation methods were used such as local minima and top hat transform.

3.4.1 Local minima

Local minima which is a morphological operation to detect the dark part in the retina after using contrast enhancement and can identify all regional minima. The functions of regional minima accept a grayscale image as input, but it return a binary image as output. In the binary image, the regional minima is set to 1 and other pixels are set to 0.

3.4.2 Median filtering

Most images are affected to some extent by noise and the process to detect the microaneurysms was interrupted by the noise. This report proposes a median filter which is non-linear filtering technique to remove the noise. Besides that, median filtering is an effective filter for noise and it is used for reducing the amount of intensity variation between one pixel and another pixel [13].

3.4.3 Top-Hat transform

Top Hat transform is in mathematical morphology and digital image processing. Top-hat transforms is based on the structure of the disc in the image and the diameter depends on the image resolution of the input image. An operation that extracts details from the images and small elements is known as Top-Hat transform [14]. The purpose of the top-hat transformation are used to detect structures of a certain size and light object on a dark background.

3.5 Detection of Microaneurysms

MAs is not appearing on the blood vessels, but it's also near with blood vessel and MAs also appear as small dots around 10 to 100 microns diameter, circular in shape and red in color. Size of MAs is set around 5 to 16 pixel [6].

3.5.1 Remove the small pixels

In this stage, the region filling and removing a small object are implemented. The function "bwareopen" which morphologically open binary is used for removing the small pixels. The opening binary image consists of erosion and dilation. It causes the image to erode or remove small pixels set by the user.

3.5.2 MAs detection

This stage is used to find the center of the MAs by using the function "imgca" in matlab. To compute the centroid of each MAs and superimposed its location on the original image. One of these particular properties of the regionprops is the centroid. This is also called as center of mass.

3.6 MAs Counting

The severity of the disease is identified by counting the number of MAs present in the resulting images. DR can be graded into four stages which is no DR, mild DR, moderate DR, and severe DR as shows in Table 1.

Table 1

Grading of Diabetic Retinopathy

Grade	DR Stage	Number of MAs
Grade 0	No DR	MA= 1
Grade 1	Mild	$1 < MA \leq 5$
Grade 2	Moderate	$5 < MA \leq 15$
Grade 3	Severe	MA > 15

3.7 Performance Evaluation

Accuracy of the proposed detection was evaluated by comparing the number of pixels obtained on the resulting images and number of pixels obtained by manually segmented images by the expert. The accuracy algorithm is given in equation (1).

$$\frac{A-B}{B} \times 100\% \quad (1)$$

where A is number of MAs counted as MAs on the resulting image and B is number of MAs counted as MAs based on manual detection. The important parameters used to measure the accuracy of the algorithms are sensitivity and specificity. There are four values to calculate the accuracy namely the true positive (TP) rate, the false positive (FP) rate, the false negative (FN) rate, and the true negative (TN) rate. The sensitivity and specificity algorithm is given in equation (2) and (3).

$$\text{sensitivity} = \frac{TP}{TP+FN} \quad (2)$$

$$\text{specificity} = \frac{TN}{TN+FP} \quad (3)$$

The true positive indicates when there an abnormal image is correctly identified as abnormal. Besides that, false negative indicates when an abnormal image is incorrectly identified as normal. The true negative indicates when a normal image is correctly shown as normal. Then, false positive is defined as normal image is incorrectly identified as abnormal.

Table 2
Result of 30 retinal image automated detection of MAs

Images	Number of MA	Grade	DR stage
Image 01	8	Grade 2	Moderate
Image 02	4	Grade 1	Mild DR
Image 03	3	Grade 1	Mild DR
Image 04	5	Grade 1	Mild DR
Image 05	7	Grade 2	Moderate
Image 06	18	Grade 3	Severe
Image 07	11	Grade 3	Severe
Image 08	2	Grade 1	Mild DR
Image 09	9	Grade 2	Moderate
Image 10	3	Grade 1	Mild DR
Image 11	3	Grade 1	Mild DR
Image 12	8	Grade 2	Moderate
Image 13	5	Grade 2	Moderate
Image 14	2	Grade 1	Mild DR
Image 15	49	Grade 3	Severe
Image 16	15	Grade 2	Moderate
Image 17	2	Grade 1	Mild DR
Image 18	1	Grade 0	No DR
Image 19	17	Grade 3	Severe
Image 20	10	Grade 2	Moderate
Image 21	1	Grade 0	No DR
Image 22	10	Grade 2	Moderate
Image 23	8	Grade 2	Moderate
Image 24	1	Grade 0	No DR
Image 25	3	Grade 1	Mild DR
Image 26	14	Grade 2	Moderate
Image 27	20	Grade 3	Severe
Image 28	1	Grade 0	No DR
Image 29	23	Grade 3	Severe
Image 30	7	Grade 2	Moderate

4. Result and Discussion

In this paper, there are 30 original retinal images were chosen from MESSIDOR and ImageRet database to be implemented with the proposed method.

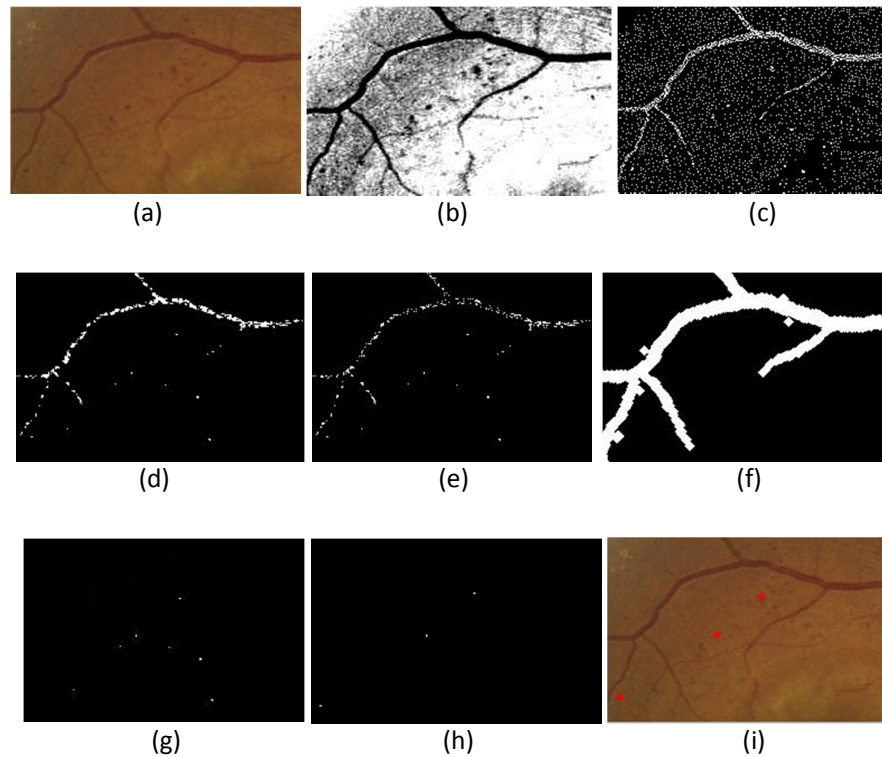


Fig. 5. Illustration of the steps in microaneurysms (MAs) detection with image (a) Input image, (b) Intensity adjusted green channel image, (c) Local Minima, (d) Median Filtering, (e) Top Hat transform, (f) Detect and remove blood vessel, (g) detected Mas, (h) pixels between 5 to 16 pixels and (i) Final MAS

The result of automated detection of MAs is shown in the Table 2. Based on the classification, 7 from all 30 images is detected as severe stage, 12 images are detected as moderate, 7 mild images and 4 images were detected as healthy which no DR.

Sensitivity is the actual MAs pixels that are detected and specificity is the non-MAs pixels that are correctly classified as non-MAs pixels. Because of the presence of noise and artifacts in the image it is difficult to achieve 100% results. This is because the ideally sensitivity and specificity is 100%. Based on the proposed approach, it can detect the MAs although in a very poor quality image. From the result in Table 3, the total average for accuracy is 99.73%, sensitivity is 97.58% and specificity is 8.98%.

Table 3
The average of Accuracy, Sensitivity and Specificity result

Images	Average of accuracy	Average Sensitivity	Average Specificity
Image 01	99.9647	99.99	9.02
Image 02	99.9398	99.89	8.41
Image 03	99.9288	99.88	9.98
Image 04	99.9247	99.99	5.63
Image 05	99.9565	99.89	8.48
Image 06	99.8567	93.43	9.37
Image 07	99.8638	99.96	8.49
Image 08	99.9315	92.94	13.29
Image 09	99.9037	99.99	19.99
Image 10	99.9168	99.31	15.43
Image 11	98.7054	92.61	8.99
Image 12	99.4502	92.94	13.29
Image 13	99.9774	98.72	9.38
Image 14	99.0405	99.88	7.48
Image 15	99.9647	93.73	19.99
Image 16	99.0842	99.99	6.46
Image 17	99.8271	92.61	15.43
Image 18	99.9398	92.94	8.42
Image 19	99.9921	98.10	9.38
Image 20	99.9315	99.31	9.99
Image 21	99.8567	92.94	19.99
Image 22	99.9999	99.99	9.37
Image 23	99.8456	99.88	9.88
Image 24	98.7023	93.73	8.99
Image 25	99.8271	99.31	2.74
Image 26	99.9972	98.72	9.94
Image 27	99.9647	99.99	19.99
Image 28	98.6932	98.72	15.43
Image 29	99.9398	99.99	7.48
Image 30	99.9956	98.10	6.46
Average	99.7307	97.58	8.98

5. Conclusion

In this algorithm, the image processing techniques was used for detection and counting the MAs. Based on the proposed approach that have been reviewed, image pre-processing and analysis algorithms are very important because it can be developed to detect the DR at the early stage. For the pre-processing method, the green channel contains more information, has high intensity and the most contrasted compared to the red and blue channel. After that, Contrast Limited Adaptive Histogram Equalization (CLAHE) was applied in the green channel image for contrast enhancement and improve the quality of the image. Then, the MAs were detected after removing the blood vessel. Detection of the MAs is done by measuring the number pixels of the MAs and compared with the manual grading by the expert. The total average for accuracy is 99.73%, sensitivity is 97.58% and specificity is 8.98%.

References

- [1] The International Agency for the Prevention of Blindness (IAPB). Diabetic retinopathy. <http://www.iapb.org/vision-2020/what-is-avoidable-blindness/diabetic-retinopathy> [Online].

- [2] Fleming, Alan D., Keith A. Goatman, Sam Philip, Graeme J. Williams, Gordon J. Prescott, Graham S. Scotland, Paul McNamee et al. "The role of haemorrhage and exudate detection in automated grading of diabetic retinopathy." *British Journal of Ophthalmology* 94, no. 6 (2010): 706-711.
- [3] Crick, Ronald Pitts, and Peng Tee Khaw. *A textbook of clinical ophthalmology: a practical guide to disorders of the eyes and their management*. World Scientific Publishing Co Inc, 2003.
- [4] Sopharak, Akara, Bunyarit Uyyanonvara, Sarah Barman, and Tom Williamson. "Automatic microaneurysm detection from non-dilated diabetic retinopathy retinal images." In *Proceedings of the World Congress on Engineering*, vol. 2, pp. 6-8. 2011.
- [5] R.N. Frank, Diabetic retinopathy, *Progress in Retinal and Eye Research* 14 (2) (1995) 361–392.
- [6] Purwita, Ardimas Andi, Kresno Adityowibowo, Ashlih Dameitry, and Made Widhi Surya Atman. "Automated microaneurysm detection using mathematical morphology." In *Instrumentation, Communications, Information Technology, and Biomedical Engineering (ICICI-BME), 2011 2nd International Conference on*, pp. 117-120. IEEE, 2011.
- [7] SujithKumar, S. B., and Vipula Singh. "Automatic detection of diabetic retinopathy in non-dilated RGB retinal fundus images." *International Journal of Computer Applications* 47, no. 19 (2012).
- [8] Muhammad Faisal, Djoko Wahono, I Ketut Eddy Purnama, Mochammad Hariadi, Mauridhi Hery Purnomo, "Classification Of Diabetic Retinopathy Patients Using Support Vector Machines (Svm) Based On Digital Retinal Image", *Journal of Theoretical and Applied Information Technology*, Vol. 59 No.1, 10th January 2014.
- [9] Patil, Shrinivas A., and Mr Avadhoot R. Telepatil. "Detection of Microaneurysm and Diabetic Retinopathy Grading in Fundus Retinal Images."
- [10] (2004) MESSIDOR: Methods for evaluating segmentation and indexing techniques dedicated to retinal ophthalmology. [Online]. Available: <http://messidor.crihan.fr/index-en.php>.
- [11] T. Kauppi, V. Kalesnykiene, J. K. Kamarainen, L. Lensu, I. Sorri, A. Raninen, R. Voutilainen, H. Uusitalo, H. Kalviainen, and J. Pietila, "DIARETDB1 diabetic retinopathy database and evaluation protocol," *Proc Medical Image Understanding and Analysis MIUA*, vol. 1, pp. 3–7, 2007.
- [12] Shin, David S., Noreen B. Javornik, and Jeffrey W. Berger. "Computer-assisted, interactive fundus image processing for macular drusen quantitation." *Ophthalmology* 106, no. 6 (1999): 1119-1125.
- [13] Phyto, Oakar, and AungSoe Khaing. "Automatic detection of optic disc and blood vessels from retinal images using image processing techniques." *IJRET: International Journal of Research in Engineering and Technology* 3, no. 03 (2014): 300-307.
- [14] Jini, MV Anifa, and Roopa Jayasingh. "Automated detection of microaneurysms to assess diabetics retinopathy." In *Electronics and Communication Systems (ICECS), 2014 International Conference on*, pp. 1-5. IEEE, 2014.