

Anil Kumar SARDA, Rakesh MITTAL

Submitted: 16 Sep 2010
Accepted: 3 Jan 2011

Department of Surgery, Maulana Azad Medical College and Lok Nayak Hospital, New Delhi 110 002, India

Abstract

Amoebic liver abscess (ALA) with jaundice and encephalopathy is a rare occurrence and has been recognised and studied more frequently in recent years. We present a case of massive ALA presenting with jaundice, hepatic encephalopathy, and septicaemia that was treated successfully with percutaneous drainage of the abscess, right-sided chest tube insertion, and anti-amoebic therapy.

Keywords: amoebiasis, hepatic encephalopathy, hepatology, jaundice, liver abscess

Introduction

Amoebic liver abscess (ALA) is the most frequent extra-intestinal manifestation of *Entamoeba histolytica* infection. It has been reported that jaundice is uncommon and mild in liver abscess, and some even consider the presence of jaundice as a feature against the diagnosis of hepatic amoebiasis (1). The cause of jaundice in a case of ALA has been hypothesised to result from either hepatocellular dysfunction or intrahepatic biliary obstruction (2). The mortality of ALA with jaundice is reported to be high. It may cause general debility and sometimes even lead to hepatic encephalopathy and septicaemia, which are the leading causes of mortality in jaundiced patients (3).

Case Report

A 24-year-old male patient presented to the surgical emergency ward with history of high-grade fever with chills and rigors of 10-day duration, along with non-radiating pain in the right hypochondrium. There was history of falling from 10 feet high 5 days prior to the onset of fever. There was also a history of yellowish discolouration of the eyes for 5 days and disorientation for 1 day. On examination, he was febrile, with a pulse rate of 120 beats/minute, and was normotensive. He was drowsy, disoriented, and deeply jaundiced. On abdominal examination, his liver was enlarged, with a span of 20 cm, and there was intercostal tenderness over the lower spaces on the right side. There was no free fluid in the abdomen.

On chest examination, there was bilateral equal air entry. Upon investigation, haemoglobin was 11 g/dL, with a total leukocyte count of 13 000 cells/mm³ (normal range is 4000–11 000 cells/mm³). Liver function tests revealed total serum bilirubin of 20 mg/dL, with direct bilirubin of 15 mg/dL, serum glutamic-oxaloacetic transaminase (SGOT) of 324 IU/L (normal level is less than 40 IU/L), serum glutamic-pyruvic transaminase (SGPT) of 340 IU/L (normal level is less than 40 IU/L), and alkaline phosphatase of 90 kAU/L (normal range is 3–13 kAU/L). The patient tested positive for amoebic serology by ELISA. A chest X-ray revealed that the right dome of the diaphragm was raised. Ultrasound showed a large hypoechoic lesion of 10 × 8 cm occupying the right lobe of the liver, suggestive of liver abscess; however, there were no ascites or pleural effusion. A computed tomographic scan showed a large mass in the right lobe of the liver with central hyperintense contents surrounded by a thick irregular hypointense rim (Figures 1 and 2). The patient was started on anti-amoebic therapy (ciprofloxacin and metronidazole), vitamin K, and intravenous fluids. His condition deteriorated over the next 24 hours, and signs of septicaemia persisted. He also developed altered sensorium. A 16F pigtail catheter was inserted into the abscess cavity under ultrasound guidance, and 100 mL of purulent fluid was drained. Subsequently, the patient developed dyspnoea, and on examination, there was dullness on the right side of the chest with the absence of breath sounds. Aspiration yielded purulent fluid, and a right-sided chest tube was inserted; 1000 mL purulent fluid was

drained. His respiration improved with the chest tube draining around 800 to 1000 mL over the initial few days. After 1 week of admission, he had profuse haematochesia. Because the bleeding profile parameters were within normal limits and in line with history of trauma, a possibility of haemobilia due to aneurysmal rupture in the abscess cavity was maintained, and an MR angiography was conducted. The MR scan revealed a large mass with central hyperintense contents surrounded by a thick irregular hypointense rim in the right lobe of the liver superiorly, but there was no evidence of aneurysm. The patient remained septicaemic for the next 4 to 5 days, but he improved slowly. The chest tube was removed on the 20th day of admission, and the drainage catheter in the abscess cavity was subsequently removed. The patient was discharged in good condition. Subsequent follow-up for 3 months and repeat ultrasound performed at the end of 3 months showed no residual abscess.

Discussion

Jaundice and encephalopathy are unusual manifestations of ALA. Most of the patients of ALA with jaundice either have multiple abscesses or a solitary large abscess compressing the biliary tract (4). In our patient, a solitary large abscess had presented with both jaundice and encephalopathy. In a series by Nigam et al. (5), cholestasis was seen in 29% of ALA cases, out of which 13% presented with hepatic encephalopathy. In a study by Vakil et al. (3), out of 58 patients with atypical presentations of ALA, 13 were found to have neurological manifestations. In a study by Kapoor et al. (6), all of the patients with neurological manifestations had multiple amoebic liver abscesses. Various hypotheses have been given for the cause of jaundice in ALA. The most accepted cause is hepatocellular dysfunction or intrahepatic biliary obstruction. Large ALA may compress the porta hepatis leading to stasis of the bile in the intrahepatic biliary radicals (7). In our case, alkaline phosphatase, serum bilirubin, SGOT, and SGPT were deranged, so both hepatocellular damage and biliary obstruction had occurred. Fifteen percent of patients may have multiple abscesses. They present with fever, toxemia, deep jaundice, and encephalopathy (8). Toxaemia is suggestive of an additional bacterial infection leading to a more severe disease. *E. coli* and *Klebsiella* are the organisms commonly cultured. Changes in the classic electroencephalography (EEG) associated with hepatic encephalopathy are high-amplitude, low-frequency waves and

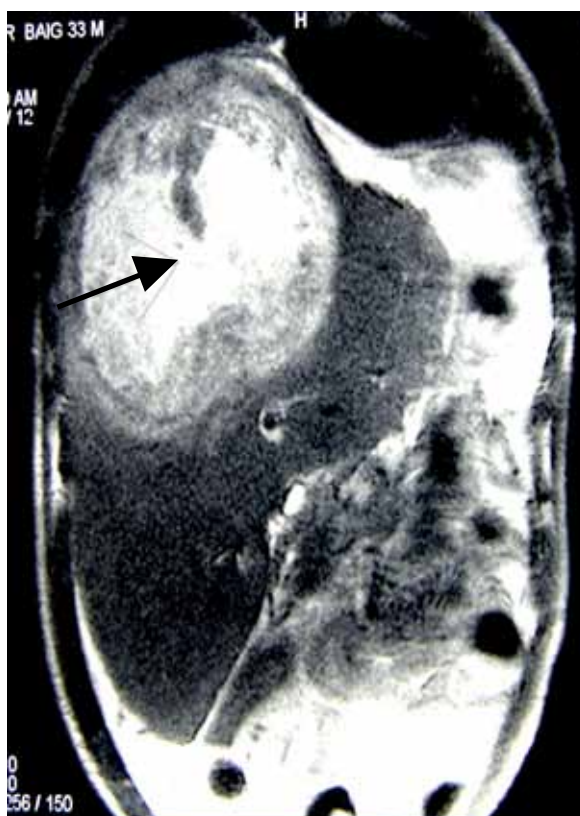

Figure 1: Computed tomography scan (coronal view) shows a large mass in the right lobe of the liver with central hyperintense contents surrounded by a thick irregular hypointense rim (arrow points to the centre of the abscess).

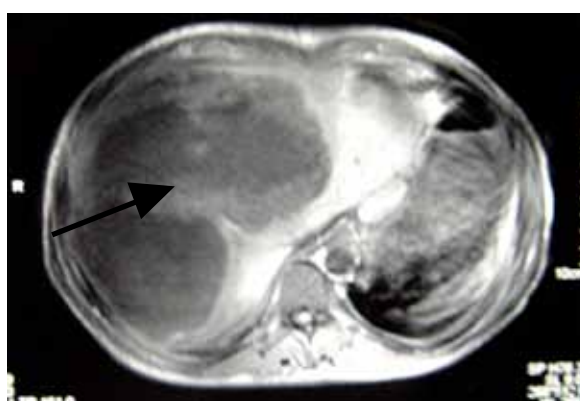


Figure 2: Computed tomography scan (axial view) of the abdomen shows a large mass with central hyperintense contents surrounded by a thick irregular hypointense rim in the superior right lobe of the liver (arrow points to the centre of the abscess).

triphasic waves (9). However, these findings are not specific for hepatic encephalopathy. Additionally, the changes in EEG are not typical enough to be useful in distinguishing hepatic encephalopathy from other conditions. Not many reports studying the changes in EEG in hepatic encephalopathy due to ALA are available in the literature.

Another unusual presentation in our case was that of haematochesia. Because there was history of trauma, the possibility of haemobilia was suspected. Causes of haemobilia include trauma, gallstones, inflammatory diseases, and vascular disorders. Though liver abscesses are known to rupture in biliary ducts, haemobilia has rarely been reported. There was therefore a dilemma regarding the cause of haematochesia in our case.

Though the treatment options vary from medical to open drainage, it is now universally accepted that aspiration and/or surgical drainage of ALA together with anti-amoebic therapy is effective (10). Our patient was managed successfully with anti-amoebic therapy and catheter drainage. Though there has been high mortality in ALA presenting with encephalopathy, our patient responded well to the treatment and was discharged in good condition.

Authors' Contributions

Conception and design, final approval of the article: AKS

Collection and assembly of data: RM

Analysis and interpretation of the data, drafting and critical revision of the article, administrative, technical, or logistic support: AKS, RM

Correspondence

Professor Dr Anil Kumar Sarda
MSurg (Delhi University), FACS, FICS, FAIS
27 RPS, Triveni-1
New Delhi-110 017
India
Tel: +0091-11-23210931
Fax: +0091-11-26672594
Email: aksarda@rediffmail.com

References

1. Abe N, Nishikawa Y, Yasukawa A, Haruki K. Entamoeba histolytica outbreaks in institutions for the mentally retarded. *Jpn J Infect Dis.* 1999;**52(3)**: 135–136.
2. Adams EB, MacLeod IN. Invasive amebiasis. II. Amebic liver abscess and its complications. *Medicine (Baltimore).* 1977;**56(4)**:325–334.
3. Vakil BJ, Mehta AJ, Desai HN. Atypical manifestation of amoebic liver abscess. *J Trop Med Hyg.* 1970;**73(3)**:63–67.
4. Guha D, Banerjee D. Serodiagnostic evaluation of amoebic hepatitis. *J Assoc Physicians India.* 1994;**42(4)**:346.
5. Nigam P, Gupta AK, Kapoor KK, Sharan GR, Goyal BM, Joshi LD. Cholestasis in amoebic liver abscess. *Gut.* 1985;**26(2)**:140–145.
6. Kapoor OP, Joshi VR. Multiple amoebic liver abscesses. A study of 56 cases. *J Trop Med Hyg.* 1972;**75(1)**:4–6.
7. Sarda AK, Kannan R, Gupta A, Mahajan V, Jain PK, Prasad S. Amebic liver abscess with jaundice. *Surg Today.* 1998;**28(3)**:305–307.
8. Sharma MP, Ahuja V. Amoebic liver abscess. *J Indian Acad Clin Med.* 2003;**4(2)**:107–111.
9. Wolf DC. Encephalopathy, Hepatic [Internet]. New York (NY); WebMD; 2010 [cited 2010 Nov 23]. Available from: <http://emedicine.medscape.com/article/186101-overview>.
10. Rajak CL, Gupta S, Jain S, Chawla Y, Gulati M, Suri S. Percutaneous treatment of liver abscesses: Needle aspiration versus catheter drainage. *AJR Am J Roentgenol* 1998;**170(4)**:1035–1039.